

Original Article

Prevalence and Severity of *Demodex folliculorum* and *Demodex brevis* Infestation and Their Association with Common Skin Diseases in Northwest Iran

*Milad Afşar¹, Khosrow Hazrati-Tappeh², Yunus Emre-Beyhan¹

¹Department of Parasitology, Van Yuzuncu Yil University Faculty of Medicine, Van, Turkey

²Department of Parasitology and Mycology, Urmia University of Medical Sciences, Urmia, Iran

*Corresponding author: Dr Milad Afşar, E-mail: mtamilad@gmail.com

(Received 26 Oct 2020; accepted 13 Mar 2024)

Abstract

Background: *Demodex* spp., a cosmopolitan mite, can exist as a commensal or parasitic organism. This study aimed to investigate the prevalence of *Demodex* spp. infestation in patients with common skin diseases and explore the potential association between demodicosis and these conditions in Urmia, northwest Iran

Methods: A total of 246 patients attending the Skin Polyclinic of Iranian Urmia Taleghani Hospital were enrolled in the study. Samples were taken from the nose wings, cheeks, and forehead regions of the face area of the persons using the standard superficial skin biopsy method.

Results: Demodicosis was detected in 43 (16.3%) patients, with 42 cases attributed to *D. folliculorum* and 1 case to *D. brevis* infestation. The highest positivity was found in the 31–50 (21.4%) and 51–72 (22.2%) age groups. In the relationship between demodicosis and skin diseases, *Demodex* spp. was found in 13 (32.5%) of 40 patients who had skin disease; 6 of these patients with rosacea (42.9%) and 7 with eczema (29.2%). Mite infestation was found in 6 (37.5%) of 16 patients who had hemodialysis due to renal insufficiency. Furthermore, 46.7% of positive patients reported using common goods. The prevalence of demodicosis was similar among patients residing in villages (17.2%) and cities (17.6%).

Conclusion: This study sheds light on the potential association between *Demodex* infestation and common skin diseases such as rosacea and eczema in Urmia, Iran. Therefore, there is a pressing need to augment research endeavors on demodicosis.

Keywords: Mite; Parasite; Rosacea; Eczema; Skin diseases

Introduction

Demodex spp. (Acariformes: Prostigmata, Demodicidae) are persistent ectoparasites in the Acarina group, primarily found in the face of people, especially on the forehead, nose, cheek, and chin areas. Two species infect humans. *Demodex folliculorum* lives in groups and settles in the infundibulum section of the hair follicle; *Demodex brevis* is more abbreviated and settles in the bottom of the sebaceous glands. Both of them feed oil for nutrition and survival. In addition, *D. folliculorum* is found in the eyebrows, eyelashes, and meibomian glands and may cause blepharitis (1, 2). *Demodex* species go through different stages in their life cycle. After approximately half a day

mating occurs and the eggs lay on the hair follicles or sebaceous glands. Three pairs of footed larvae hatch and become adults after two nymph stages. Mites have a short life span of 14–18 days and spend their entire life on the host. They are seen worldwide and in every race, but the prevalence of infestation increases with advancing age (2–4). In different study groups, the infestation rate generally varies between 17% and 72% in healthy people and reaches up to 100% in elderly people (9). In Iran, *Demodex* mites were found in 55% of university students (18) and 20% among a young group (20).

The mite is transmitted through the use of

common goods, close contact, and not paying attention to hygiene conditions. It becomes pathogenic with increasing numbers. It is argued that this mite lives commensally without any pathology but becomes a pathogen due to reasons such as frequent use of cosmetic products on the skin, not cleaning the face well, increased sebum secretion especially with sweating in hot weather and using steroids. *Demodex* sp. can cause abscess formation by creating a suitable area for the reproduction of bacteria, strong skin reactions, and obvious pigmentation. In addition, these mites have been reported to play an important role in the etiology and pathogenicity of dermatoses such as acne vulgaris, rosacea, eczema, perioral and seborrheic dermatitis, folliculitis, and blepharitis. However, the severity of the pathology varies depending on the age factor and the state of the immune system (2, 8).

In the clinical diagnosis of demodicosis, cellophane tape, skin scraping, and punch biopsy methods as well as noninvasive standardized skin surface biopsy (SSSB) are used. In samples prepared using cellophane tape and skin scraping, it is possible to detect only mites that move freely on the surface. However, since mites are generally found in the lower part of the hair follicles, the SSSB method, which examines the corneum layer of the skin and the follicle content together, is often preferred (1, 2, 8).

This study aimed to investigate the frequency of demodicosis, whose importance is increasing, by taking into account the characteristics and socio-economic status of patients applying to the Dermatology Clinic in Urmia, Iran. In addition, it was targeted to reveal the relationship between demodicosis and skin diseases, to raise awareness of the community in dealing with this mite, and to increase the application of tests that are cost-effective in diagnosis.

Materials and Methods

The study was conducted on 246 patients,

of whom 118 (48%) were females and 128 (52%) were males, who were applied to the Dermatology Polyclinic of Taleghani Training Research Hospital in Urmia City of Iran between January and August 2017. Patients aged between 9 and 72 years were divided into four groups: 9–17 years, 18–30 years, 31–50 years and 50–72. There were 45, 122, 70, and nine individuals in these groups, respectively.

Four separate preparations were prepared from samples taken from the nose wings, chin, cheek, and forehead regions of the patients using the SSSB method.

To receive a sample, a drop of cyanoacrylate adhesive was dropped on the slide and the slide was attached to the specimen face area. After waiting for about a minute, the slide was carefully pulled out, a drop of Hoyer solution was added to the slide before drying, and the coverslip was closed (2). The preparations were then examined in a light microscope with magnifications of 100 and 400. When the samples were evaluated, if five or more mites were observed in one cm² area, the patient was considered positive.

Information about the age, gender, marital status, place of residence (city or village), educational status, profession, use of common goods, and whether there were skin diseases or any diseases were recorded.

Descriptive statistics of continuous variables in our investigation are articulated through the utilization of mean, standard deviation, minimum, and maximum values. In contrast, categorical variables are expressed as numerical and proportional values. The determination of the relationship between demodicosis and categorical variables was conducted through the implementation of the Chi-square test. The statistical significance was established at a 5% level of significance for calculations, with the aid of SPSS (IBM SPSS for Windows, ver.23)

Results

Considering the demographic characteris-

tics of the patients, 99 were married and 147 were single; 58 of them lived in the village and 188 lived in the city. Individuals' education levels were as follows; 15 people were illiterate (never studied), 80 people were educated in primary and secondary school, 73 were educated in high school, 32 were educated at university, 36 were undergraduate students and 10 were graduate students. Forty (16.3%) of the 246 examined patients had various skin diseases, 14 of which were rosacea, 24 were eczema, and 2 were acne.

A total of 43 (17.5%) patients were detected positive for demodicosis. *Demodex folliculorum* was detected in the nose wings and cheeks of 42 patients, while *D. brevis* was found in the forehead of an 18-year-old male. 17% (20/118) of females and 18% (23/128) of males were infested with mites. *Demodex* spp. positivity in genders was found to be similar, and no statistically significant relationship was detected ($p=0.833$) (Table 1). Parasites were detected in 5 patients (11.1%) in the 9–17 age group, 21 patients (17.2%) in the 18–30 age group, 15 patients (21.4%) in the 31–50 age group, and 2 patients (22.2%) in the 51–72 age group, and no associated detected with infestation and age ($p=0.538$) (Table 2). Considering the relationship between *Demodex* spp. positivity and marital status, 21% of married individuals and 15% of singles were found positive ($p=0.206$). The incidence of demodicosis was not significant according to the place of residence; it was 17.2% (10/58) in villages and 17.6% (33/188) in urban areas ($p=0.959$). Related to education level, 13.3% (2/15) of illiterate students, 18.8% (15/80) of primary and secondary school students, 17.8% (13/73) of high school students, 28.1% (9/32) of university students, 11.1% (4/36) of undergraduates were found to be positive, and no parasite was detected in postgraduates ($p=0.314$).

Demodex was detected in 14.6% (30/206) of people without any skin disease and in 32.5% (13/40) of people with skin disease ($p=0.022$) (Table 3). In addition, blepharitis was

found in one person (2.3%) infected with *D. folliculorum* (Fig. 1). Moreover, 42.9% (6) of 14 patients with rosacea, and 29.2% (7) of 24 patients with eczema were positive, whereas parasites were not observed in two patients with acne (Fig. 2). The relationship between skin diseases and demodicosis was found to be statistically significant ($p=0.017$).

In the survey asking whether common substances were used, 21 out of 246 patients stated that they used common substances, and mites were detected in 46.7% (10) of them and in 14.7% (33) of those who did not use public goods. Statistically, the use of common items increases demodicosis ($p=0.001$). It was determined that 16 of the individuals were on hemodialysis due to kidney failure. Demodicosis was detected in 37.5% of these patients and 16.1% of those who did not receive hemodialysis ($p=0.008$).



Fig. 1. *Demodex folliculorum* detected in a positive patient in Urmia Taleghani Hospital, 2018 (Original)

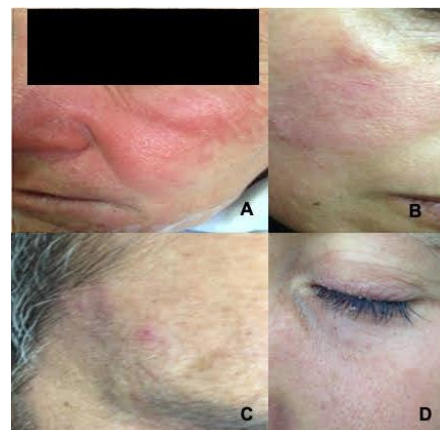


Fig. 2. *Demodex* with rosacea (A), eczema (B), acne (C), and blepharitis (D), in Urmia Taleghani Hospital, 2018 (Original)

Table 1. *Demodex* spp. positivity according to education level, living area, marital status, and gender, Urmia City, Iran, 2018

	<i>Demodex</i> positive (%)	<i>Demodex</i> negative	Total	P value
Education level				0.314
Illiterate	2 (13.3)	13	15	
Primary and secondary school	15 (18.8)	65	80	
High school	13 (17.8)	60	73	
University	9 (28.1)	23	32	
Undergraduates	4 (11.1)	32	36	
Postgraduates	0 (0)	10	10	
Living area				0.959
Rural	10 (17.2)	48	58	
Urban	33 (17.6)	155	188	
Marital status				0.206
Married	21 (21.2)	78	99	
Single	22 (15)	125	147	
Gender				0.833
Female	20 (17)	98	118	
Male	23 (18)	105	128	

Table 2. *Demodex* spp. infestation by age group in Urmia, Iran, 2018

<i>Demodex</i> spp.	Age groups				Total
	9–17	18–30	31–50	51–72	
Positive (+)	5 (%11.1)	21 (%17.2)	15 (%21.4)	2 (%22.2)	43 (%17.5)
Negative (-)	40	101	55	7	203
Total	45	122	70	9	246

Table 3. Relationship between *Demodex* spp. positivity and skin disease, Urmia, Iran, 2018

<i>Demodex</i> spp.	Skin disease (+)	Skin disease (-)	Total
Positive (+)	13 (32.5%)	30 (14.6%)	43 (17.5%)
Negative (-)	27	176	203
Total	40	206	246

Discussion

Despite the controversial pathogenicity of *Demodex* species, dermatological disorders have been reported to be effective in the etiopathogenesis of infestation, and changes in the immune system play a role in the occurrence of the pathogen state. Acne vulgaris, rosacea, and seborrheic dermatitis are the main diseases thought to be caused by this mite. Therefore, the diagnosis of demodicosis is significant for treating dermatological disorders (1, 2).

The best treatment against this mite is the application of drugs containing permethrin, lin-

dane, and crotamiton, as in scabies. It is recommended that creams containing 5% permethrin, the most effective drug against *D. folliculorum*, be applied to the face as a mask. Reinfestation may occur due to symptoms such as edema, flushing, and itching that may occur on the face due to the death of the mites. It is also known that 4% pilocarpine gel eliminates the symptoms during the treatment process in cases of blepharitis caused by *Demodex* spp. It should not be forgotten that this mite, which is known to be transmitted through

direct contact as well as shaking hands and kissing, may die in dry environments. To prevent infestation, skin cleansing with soap and water at regular intervals and not using shared towels prevent reinfection in patients receiving treatment (24).

Demodex folliculorum and *D. brevis* live in the sebaceous glands and infundibulum section of the hair follicles, especially in the forehead, nose, eyelash, and ear areas (2). Demodicosis can be diagnosed by various methods such as SSSB, punch biopsy of follicles in lesioned areas, skin scraping method, or cellophane tape. SSSB, which is a noninvasive method, is often preferred in practice because it allows the examination of the follicle content along with the corneum layer of the skin (2, 4). However, the success of the SSSB method varies depending on the skill of the implementer. In this study, the patients approached the SSSB method positively and no difficulty was observed in the detection of this mite.

The prevalence of *Demodex* was investigated in various patient groups and many parts of the world. This mite infestation was reported in 11.6% and 67.6% of university students in China (9, 10), 17.2% of patients with facial skin diseases in Malaysia (11), and 20% of 1010 individuals (5) in whom eyelashes were examined in Mexico. The first case of *Demodex* in Turkey was detected in preparations made from the patient's perianal region using the cellophane-tape method (12). *Demodex* was detected in 2.9% of university students in Kayseri (13), 74.7% of people consisting of laboratory workers, kitchen personnel, cleaning workers, and nurses (14), 47.4% of students of the Faculty of Health Sciences (15) and 62.3% of 300 volunteers in Erzincan (16). There were very few studies on the prevalence of demodicosis in Iran. The infestation was found in 78% of patients suspected of skin diseases and leprosy (17), 31.7% of patients with mild dermatologic complaints (mild itching or scaling or erythema) (18), 4.54% and 55% of university students (6, 19), 20.6% of healthy

individuals (20) and 20% among youth individuals (7). In this study, we detected 17.5% positivity in randomly selected patients was applied to the dermatology clinic in Urmia City, Iran. Although this rate is lower than that in studies conducted in special patient groups, it reflects the general prevalence and was found close to randomly selected groups. The main reason why the study results differ from each other is that the presence of *Demodex* is primarily affected by age and dermatological patient groups. However, hygiene habits in the region where the study is conducted and knowledge about infestation over time may be effective in reducing the prevalence.

This mite is rarely seen in children due to the low production of sebum excretion, so the density increases with age (2, 16, 21). The incidence of *Demodex* is approximately 95% in individuals over the age of 71. It occurs in 69% of individuals between the ages of 31 and 50 and in only 13% of individuals between the ages of 3 and 15 (22). Rusiecka-Ziolkowska et al. (8) mentioned that the infestation is often diagnosed after the age of 70. In a previous study, no parasites were found under 20 years of age, whereas positivity was found in 33% of the 20–29 age group and 73.3% of the 60–69 age group (25). In another study, the mite was found in 33.6% of the 13–16 age group, and 92.8% of the 18–22 age group (10). In parallel with these, we detected the highest positivity at the ages of 31–72. The effect of gender on *Demodex* infestation is controversial; male-dominant, female-dominant, or gender-independent studies are available (2, 17). Most studies indicate that men are generally more severely infested than women (26). Zhao et al. (10) encountered 59% positivity in both sexes, while Yazısız et al. (21) found it approximately 70% in females, Shokrani et al. (6) and Tilki et al. (16) detected that it is more frequent in males. In many studies, the effect of living area on infestation was not observed (10, 21), however, it was found to be high in old buildings (25) or the

city (27) without any significant difference. It was stated that low socioeconomic levels increased *Demodex* positivity approximately 2.3 times (27). As with all infectious agents in general, the prevalence of *Demodex* decreases as the education level increases. Yazısız et al. (21) encountered fewer infestations among university graduates than among primary and high school graduates. Also, Tilki et al. (16) indicated that people with a low level of education are more at risk. Moreover, the same researchers found that the infestation was more intense in married people. This may be related to more contact, although there is no evidence for this. In this study, we determined that demodicosis is not related to sex, place of residence, and education level. Considering the increase of demodicosis prevalence with the use of common items, as seen in this study, it is important to avoid the common use of hand and face towels, underwear, and bedspreads to prevent demodicosis.

The pathogenic role of *Demodex* mites in humans remains unclear. This mite is considered commensally in normal skin and lived in an asylum without causing any clinical manifestations. *Demodex* infestation damages the skin barrier by mechanical blocking of the hair follicles and sebaceous glands, especially when their number increases. It has been suggested that *Demodex* mite causes an inflammatory reaction that can create dermal collagen degeneration (1, 2, 23, 28–30). Additionally, the proliferation of *Demodex* is associated with dermatoses, such as rosacea, folliculitis seborrheic dermatitis, perioral dermatitis, folliculitis, abscesses, and blepharitis (2, 26). Although it is thought that *Demodex* is not a dominant factor leading to rosacea, there is a statistically significant relationship between mite density and rosacea (29, 31). However, the pathogenic mechanism has not yet been described (8).

Many studies have shown that *Demodex* is more effective in patients with rosacea. Even in one study, this rate was found to be 5.7

times higher (32), and in another one, the mite density in biopsy samples was determined as 10.8/m² (29). Yazısız et al. (21) detected *Demodex* in 69.9% of patients with dermatological complaints on the face. The mite prevalence was determined as 100%, 77.1%, 75%, 57%, and 40% in patients with pityriasis rosacea, acne rosacea, contact dermatitis, seborrheic dermatitis, and acne vulgaris, respectively. Similarly, 60.7% positivity was detected in patients with rosacea (33), 66.7% in blepharitis, 81.9% in acne vulgaris, and 64.3% in seborrheic alopecia (10). In another study, *D. folliculorum* was reported in 96% of 48 rosacea patients (32). While *Demodex* was found in 24 of 41 patients with rosacea (31 erythematotelangiectatic rosacea and 10 papulopustular rosacea), it was detected in only eight of 41 patients in the control group (34). In Iran, the infestation was found to be significantly higher in patients with acne vulgaris and rosacea (6, 20). Moravvej et al. (28) were detected as positive in 38.6% of 75 acne rosacea patients in Tehran. Forton and Seys (29) also detected that the mite was more common in papulopustular rosacea cases, among all rosacea types. In this study, individuals were analyzed according to skin diseases to determine whether *Demodex* mites are pathogens or not, and *Demodex* was detected in 43.3% of patients with skin disease; 42.9% with rosacea, and 29.2% with eczema. Therefore, it is thought that demodicosis may play an important role in people with skin disease.

Besides, *Demodex* is pathogenic, especially in cases of immune deficiency, such as patients with leukemia, HIV infection, chronic renal failure, diabetes, chronic dialysis, and cancers (2, 26, 29, 35). Long-term use of local steroids or other immunomodulatory drugs can increase mite density (36). The detection of mite infestation was approximately seven times more than that in the control group (4.7/cm²) suggesting that immunosuppressive therapy could disrupt defense mechanisms (37). Intense *Demodex* infestation has been report-

ed to cause a facial eruption in patients with lymphoma or leukemia (38). In HIV– positive patients, demodicosis may appear with an itchy rash on the face, especially when the CD4+ drops below 200/mm³ (39). In a study conducted on 101 cancer patients to investigate the incidence of *Demodex* species, 77 (76.2%) were found to be positive. Mite infestation was found in 18 of 38 cases of breast cancer, 7 of 24 cases of lung cancer, 5 of 27 cases of gastrointestinal system cancer, and 2 of 12 cases of urogenital system cancer (40). Malnutrition and malignancy are also important risks for *Demodex* mites and increased the positivity by 17.3 and 27.2 times, respectively (27). More mite infestation was also reported in diabetic patients. In one study, *D. folliculorum* positivity was detected in 43.7% of patients with diabetes mellitus and only 3.3 % of the control group (41). In another study, the infestation was found in 54.8% of 42 diabetic patients (42). In this study, a significant relationship was found between patients undergoing hemodialysis and mite positivity with a 37.5% rate.

Conclusion

There are very few studies on *Demodex* infestation in Iran, where this study was conducted. This is the first investigation into the relationship between skin diseases and *Demodex* mites in Urmia City. In this context, it will be beneficial to conduct more research on this mite.

It is important to note that the *Demodex* mite is more common in people with skin disease, especially in rosacea, eczema, acne, seborrheic dermatitis, psoriasis, and blepharitis. These have been identified as factors that can aggravate the picture. Today, the presence of *Demodex* is not sufficiently emphasized, so the presence of mites should be considered, especially in patients with skin diseases and resistant to treatment.

Acknowledgements

The costs of the study were covered by the authors.

Ethical consideration

Urmia University of Medical Sciences Biological Sciences Ethics Committee approved the study protocol (11.02.2017-p6/95/4/213167).

Conflict of interest statement

The authors declare there is no conflict of interest.

References

1. Lacey N, Kavanagh K, Tseng S (2009) Under the lash: *Demodex* mites in human diseases. *Biochem.* 31(4): 2–6.
2. Litwin D, Chen W, Dzika E, Korycinska J (2017) Human permanent ectoparasites; recent advances on biology and clinical significance of *Demodex* Mites: Narrative Review Article. *Iran J Parasitol.* 12 (1): 12–21.
3. Dong H, Duncan LD (2006) Cytologic findings in *Demodex* folliculitis: a case report and review of the literature. *Diagn Cytopathol.* 34: 232–234.
4. Akilov OE, Butov YS (2005) A clinic pathological approach to the classification of human demodicosis. *J Dtsch Dermatol Ges.* 3: 607–614.
5. Vargas-Arzola J, Reyes-Velasco L, Segura-Salvador A, Marquez-Navarro A, Diaz-Chiguer DL, Noguera-Torres B (2012) Prevalence of *Demodex* mites in eyelashes among people of Oaxaca, Mexico. *Acta Microbiol Immunol Hung.* 59 (2): 257–262.
6. Shokrani H, Nabavi R, Sarabi ZA (2015) Demodicosis and associated risk factors

- in young adults in Khorramabad. Arak Med Univ J. 2016; 19(108): 38–45.
7. Taghi Rahimi M, RezaYoussefi M, Ahmadpour E (2016) Prevalence of demodicosis among youth in Northern Iran. J Zoon Dis. 1: 54–57.
 8. Rusiecka-Ziółkowska J, Nokieli M, Fleischer M (2014) *Demodex*—an old pathogen or a new one? Adv Clin Exp Med. 23(2): 295–298.
 9. Ding Y, Huang X (2005) Investigation of external auditory meatus secretion *Demodex folliculorum* and *Demodex brevis* infection in college students. Lin Chuang Er Bi Yan Hou Ke Za Zhi. 19(4): 176–177.
 10. Zhao YE, Guo N, Xun M, Xu JR, Wang M, Wang DL (2011) Sociodemographic characteristics and risk factor analysis of *Demodex* infestation (Acari: Demodicidae). J Zhejiang Univ Sci B. 12(12): 998–1007.
 11. Isa NH, Loong LW, Fang GH, Mohamad AM, Razali N, Rani NI, Manap SN, Abdullah SR (2011) Demodicosis among university medical students in Malaysia and the effects of facial cleanser and moisturizer usage. Southeast Asian J Trop Med Public Health. 42(6): 1375–1380.
 12. Saygı G, Marufi M, Köylüoğlu Z (1984) Biri selofanlı bant preparatı ile saptanan üç *Demodex folliculorum* olgusu (In Turkish). Türkiye Parazitoloj Derg. 7: 137–144.
 13. Yazar S, Ozcan H, Cetinkaya U (2008) Investigation of *Demodex* sp. using cellophane tape method among university students. Türkiye Parazitoloj Derg. 32(3): 238–240.
 14. Yuca Fırat P, Gecit İ, Depecik F, Karadan M, Karıcı E, Karaman U (2010) *Demodex* spp. positivity among laboratory staff, kitchen staff, cleaning workers and nurses working in a state hospital. Türkiye Parazitoloj Derg. 34: 164–167.
 15. Özdemir H, Özer E, Özdemir S, Alkanat M (2015) The prevalence of *Demodex* species in faculty of health science students. Arch Turk Dermatol Venereol. 49: 139–141.
 16. Tilki E, Zeytun E, Doğan S (2017) Prevalence and density of *Demodex folliculorum* and *Demodex brevis* (Acari: Demodicidae) in Erzincan Province. Türkiye Parazitoloj Derg. 41(2): 80–86.
 17. Daneshparvar A, Hajjaran H, Mobedi I, Naddaf S, Nateghpour M, Makki MS, Shidfar M, Hashemi J, Eskandari E, Mowlavi GH (2014) Infestation of patients to demodicosis referred to the skin clinics and its relation to some related factors in Tehran, Iran. Sci J Sch Publ Health Inst Pub Health Res. 12: 53–59.
 18. Tehrani S, Tizmaghz A, Shabestanipour G (2014) The *Demodex* mites and their relation with seborrheic and atopic dermatitis. Asian Pac J Trop Med. 7S1: S82–S84.
 19. RezaYoussefi M, Pour RT, Rahimi MT (2012) Prevalence of *Demodex* mites (Acari: Demodicidae) parasitizing human in Babol, North of Iran. Academic J Entomol. 5: 62–64.
 20. Talghini SH, Shenasi R, Fouladi DF, Haggi A (2014) *Demodex folliculorum* and skin disease: a case-control study. J Med Sci. 5: 229–234.
 21. Yazısız H, Çekin Y, Koçlar FG (2019) The presence of *Demodex* mites in patients with dermatologic symptoms of the face. Türkiye Parazitoloj Derg. 43(3): 143–148.
 22. Czepita D, Kuzna-Grygiel W, Kosik-Bogacka D (2005) Investigations on the occurrence as well as the role of *Demodex folliculorum* and *Demodex brevis* in the pathogenesis of blepharitis. Klin Oczna. 107: 80–82.
 23. Dhingra KK, Saroha V, Gupta P, Khurana N (2009) *Demodex*—associated dermatologic conditions—a coincidence or an etiological correlate. Review with a report

- of a rare case of sebaceous adenoma. *Pathol Res Pract.* 205(6): 423–426.
24. Yolaşığmaz ÜA, Turgay N (2005) Treatment in Medical Parasitology. *Türkiye Parazitol Derg*, No: 20, İzmir.
 25. Wesolowska M, Knysz B, Reich A, Blazejewska D, Czarnecki M, Gladysz A, Pozowski A, Misiuk–Hojlo M (2014) Prevalence of *Demodex* spp. in eyelash follicles in different populations. *Arch Med Sci.* 10(2): 319–324.
 26. Elston CA, Elston DM (2014) *Demodex* mites. *Clin Dermatol.* 32(6): 739–743.
 27. Kaya S, Selimoglu MA, Kaya OA, Ozgen U (2013) Prevalence of *Demodex folliculorum* and *Demodex brevis* in childhood malnutrition and malignancy. *Pediatr Int.* 55(1): 85–89.
 28. Moravvej H, Dehghan-Mangabadi M, Abbasian MR, Meshkat-Razavi G (2007) Association of rosacea with demodicosis. *Arch Iran Med.* 10(2): 199–203.
 29. Forton F, Seys B (1993) Density of *Demodex folliculorum* in rosacea: a case-control study using standardized skin-surface biopsy. *Br J Dermatol.* 128: 650–659.
 30. Chen W, Plewig G (2014) Human demodicosis: revisit and a proposed classification. *Brit J Dermatol.* 170(6): 1219–1225.
 31. Moran EM, Foley R, Powell FC (2017) *Demodex* and rosacea revisited. *Clin Dermatol.* 35: 195–200.
 32. Casas C, Paul C, Lahfa M, Livideanu B, Lejeune O, Alvarez-Georges S, Saint-Martory C, Degouy A, Mengeaud V, Ginisty H, Durbise E, Schmitt AM, Redoules D (2012) Quantification of *Demodex folliculorum* by PCR in rosacea and its relationship to skin innate immune activation. *Exp Dermatol.* 21(12): 906–910
 33. Yücel A, Yilmaz M (2013) Investigation of the prevalence of *Demodex folliculorum* and *Demodex brevis* in rosacea patients. *Türkiye Parazitol Derg.* 37: 195–198.
 34. Gonzalez-Hinojosa D, Jaime-Villalonga A, Aguilar-Montes G, Lammoglia-Ordiales L (2018) *Demodex* and rosacea: Is there a relationship? *Indian J Ophthalmol.* 66(1): 36–38.
 35. Karıncaoglu Y, Esrefoglu Seyhan M, Bayram N, Aycan O, Taskapan H (2005) Incidence of *Demodex folliculorum* in patients with end stage chronic renal failure. *Ren Fail.* 27(5): 495–499.
 36. Fujiwara S, Okubo Y, Irisawa R, Tsuboi R (2010) Rosacei form dermatitis associated with topical tacrolimus treatment. *J Am Acad Dermatol.* 62(6): 1050–1052.
 37. Gerber PA, Kukova G, Bühren BA, Homey B (2011) Density of *Demodex folliculorum* in patients receiving epidermal growth factor receptor inhibitors. *Dermatol.* 222: 144–147.
 38. Seyhan ME, Karıncaoglu Y, Bayram N, Aycan O, Kuku I (2004) Density of *Demodex folliculorum* in haematological malignancies. *J Int Med Res.* 32: 411–415.
 39. Clyti E, Sayavong K, Chanthavisouk K (2005) Demodecidosis in a patient infected by HIV: successful treatment with ivermectin. *Ann Dermatol Venereol.* 132: 459–461.
 40. Sönmez ÖU, Yalçın ZG, Karakeçe E, Çiftci İH, Erdem T (2013) Associations between *Demodex* species infestation and various types of cancer. *Acta Parasitol.* 58(4): 551–555.
 41. Arlı C, Ozsan M, Gurkan E, Aycan Kaya O, Kokacya S (2019) The incidence of *Demodex folliculorum* in the combination of allergic rhinitis and diabetes mellitus. *Iran J Parasitol.* 14(3): 459–464.
 42. Yamashita LS, Cariello AJ, Geha NM, Yu MC, Hofling-Lima AL (2011) *Demodex folliculorum* on the eyelash follicle of diabetic patients. *Arq Bras Oftalmol.* 74: 422–424.