

Case Report

Gastrointestinal Myiasis Due to *Sarcophaga argyrostoma* (Diptera: Sarcophagidae) in Mashhad, Iran: A Case Report

*Mohsen Najjari¹; Bilal Dik²; Gamze Pekbey³

¹Department of Parasitology and Mycology, Faculty of Medicine, Mashhad University of Medical Sciences, Mashhad, Iran

²Department of Parasitology, Faculty of Veterinary Medicine, Selçuk University, Selçuklu, Konya, Turkey

³Department of Plant Protection, Faculty of Agriculture, Bozok University, Yozgat, Turkey

*Corresponding author: Dr Mohsen Najjari, E-mail: najjarimh@mums.ac.ir

(Received 07 Jan 2019; accepted 05 Jul 2020)

Abstract

Myiasis is infection with a fly larva, usually occurring in tropical and subtropical areas. A 32-years-old immunocompromised woman with fever, gastrointestinal pain, cramps, vomiting; and fatigue was referred to Ghaem Hospital in Mashhad in July 2018. Entomological characterisation of cephaloskeletons, posterior spiracles of the excreted larvae and genital dissection of male fly were diagnosed as *Sarcophaga (Liopygia) argyrostoma*. Accidental intestinal myiasis caused by unplanned intake of dipterous larvae by contaminated food staff or water. Patients with immune deficiency may be more at risk for the threat of maggot's infestation, so in such cases, hospital standard should be more in attention. To best of our knowledge, *S. argyrostoma* has not been reported before in the indexed literature from Iran.

Keywords: *Sarcophaga argyrostoma*; Intestinal myiasis; Iran

Introduction

For many years human body cavities have been attacked by insects' larvae. The word myiasis has been derived from ancient Greek language in which "Mya" means fly and "iasis" means disease (1). Afterward, in year 1840 the term "myiasis" appeared to describe a human ailment that arose from dipterous maggots (2). More recently, it has been more cleared and depicted as invasion of live vertebrate animals and human with fly maggots which in any event for a specific period, feed on the host's dead or living tissue, liquid body substances, or ingested sustenance (3).

In general, it starts when gravid female flies are attracted by the odors of infected wounds, decaying organic matter, feces, urine, and human food, where they deposit larvae or eggs (4) and principally, classified in two groups: entomologically and anatomically. From entomological aspect, it can be classified into two major categories named primary and secondary my-

iasis. In primary myiasis larvae more found in animals, and rarely found in humans and feeding on living tissue in other side, flies could feed on dead tissues and necrotic lesions in patients known as secondary myiasis. It also classified according to the anatomy and position involved in the host body and had classified as oral, nasopharyngeal ocular, cutaneous, urogenital and intestinal (5). Myiasis can be also classified as obligatory, facultative and accidental. This also categorize as entomological point of view (6). Myiasis of the intestinal tract (=intestinal myiasis) caused by accidental ingestion of dipterous eggs or larvae usually transited and asymptomatic. The flies that cause gastrointestinal myiasis usually are the members of the families Sarcophagidae and Muscidae (7).

The aim of the study was to report intestinal myiasis that is uncommon in Iran though so far there are just three reports of *Sarcophaga (Bercae) africa* (as *S. haemorrhoidalis*), *Eristalis*

tenax and *Lucilia illustris* can be seen in literature (8, 9).

Case description

A 32 years-old woman from Golestan Province was referred to Ghaem Hospital in Mashhad, northeastern Iran with fever, weakness, gastrointestinal pain, cramps, vomiting, fatigue and weight loss in July 2018. Her main complication was lasted profound and repeated watery diarrhea started since six months ago. She had a double kidney transplant history seven years ago. Other significant clinical results were: Hb: 8, WBC: 3400, CRP: +++ and ESR: 100, CD4 102, level of cyclosporine in her sera was 3.5. She was before roll out for HIV, HCV, HTLV1, *Cryptosporidium* spp., *Entamoeba histolytica*, *Toxoplasma gondii* and intestinal tuberculosis due to flask like wound in her the large intestine appeared in colonoscopy. Complementary diagnostic process was performed and cytomegalovirus confirmed by real time-PCR. She was treated with Ganciclovir (5% (oral), Hoffmann La Roche) and using a standard protocol. After ten days of her remedy and subside of her gastric pain and diarrhea due to new complaints of abdominal spasms, gastric pain and diarrhea a new stool sample was sent to parasitology laboratory. The result was negative for parasite but in macroscopic examination 15 whitish moved worm like observed that later confirmed for maggots of a fly. To investigate whether the feces were infested by larvae from the canteen in which the patient was defecating a sigmoidoscopy was performed in next day and feces directly obtained from the large intestine. The sample was examined and appeared the presence of five live maggots. Due to the threat of maggot tissue penetration, the patient was situated under colonoscopy to examine the presence of bare larvae in the tissue. There were no larvae although in her biopsy milled inflammatory cells were seen and also evidence of wounds healing showed no additional antibiotic and the extra drug prescribed because of any evidence of con-

tinued infestation in her next stool samples examination. Due to the advent of symptoms of healing, get a relative general improvement and disappearance of diarrhea and gastrointestinal symptoms by complete exertion of larvae, after three week of hospitalization, she was temporarily discharged from the hospital regarding her request to continue the treatment at home.

In the Laboratory of Parasitology, Ghaem Hospital at first glance and macroscopic examination of feces, the larvae were miss-diagnosed as pinworms (10) by lab technician while in microscopic examination afterward they were detected as the early stage of unknown fly larvae. Obtained wormy like creature was washed using phosphate-buffered saline solution (pH: 7.4). To early diagnosis the larvae one of them cleared by lactophenol and examined again under a light microscope. Five live cylindrical maggots measured they were around 9mm in length and 3mm in diameter and transferred on blood agar medium which usually used for microbiology investigation. After three days the larvae grow as instars III. Three of them saved and fixed by formalin 10% for further larval diagnosis and transferred to Department of Parasitology, Veterinary Faculty of Selçuk University in Konya, Turkey while the remained two other transferred in a garden soil glass jar (5cm high), they immediately penetrated deep into the soil. Five days later, pupas were observable and photographed when they were gently removed from the soil. Finally, after ten days, two adult flies appeared (Fig. 1). The adult flies transferred in a carton box to the Entomology lab in Bozok University, Yozgat, in Turkey for the identification. The other early stage larvae were preserved in ethanol 70% and save in the collection of Museum of Mashhad University of Medical Sciences using assigned voucher numbers.

The larvae washed by distilled water, transferred to ethanol 70% and 99% for a few hours in each step, dissected and mounted on the slides in Canada balsam. They were examined, and captured photos of cephaloskeleton,

anterior and posterior spiracles with Nikon SMZ camera mounted stereo zoom microscope with Toupcam U3CMOS application unit, and Leica DM750 camera mounted trinocular microscope with Leica DFC295 application unit. The larvae were identified as two and third instars of *Sarcophaga* spp. (Diptera: Sarcophagidae) (11). The body of larva in follows the general pattern of Sarcophagidae, i.e., anterior spiracles are seen (Fig. 2). The third instar of *S. argyrostoma* was easily recognizable from second instar larva; it has three slits in each one of posterior spiracles by the presence of two slits in posterior spiracles (Figs. 3, 4). The larva

had a pair of strong oral hooks and a cephaloskeleton (Figs. 5, 6).

In the Entomology lab at Bozok University, genital dissection of the adult male was performed under Leica S8APO stereomicroscope; only the fifth abdominal sternite was softened for 24h in a cold solution of 10% KOH to facilitate the further dissection. Identification, classification, and terminology followed and, the specimen was identified as *S. (Liopygia) argyrostoma* (Fig. 7) (12). Digital photos of the genitalia were captured with Leica MZ 125 camera mounted stereo zoom microscope and Leica application suite (ver. 3.8.0).



Fig. 1. Adult fly of *Sarcophaga argyrostoma* appeared in Parasitology lab, Ghaem hospital, Mashhad, July 20, 2018

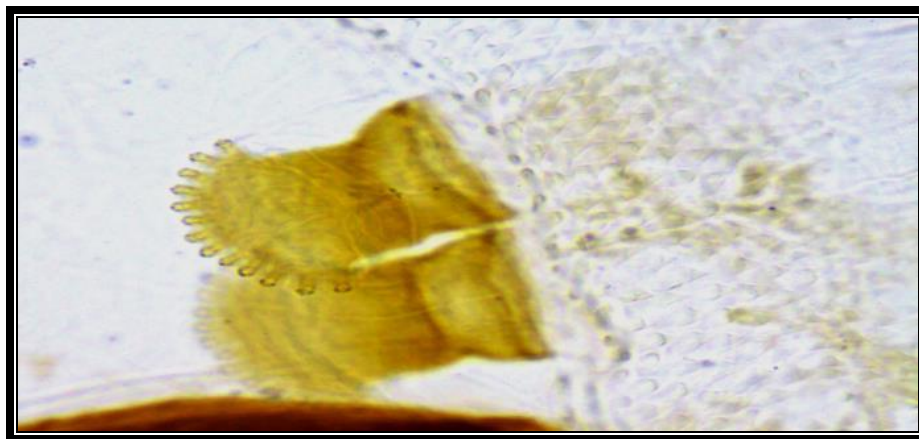


Fig. 2. *Sarcophaga argyrostoma*, third instar larva, anterior stigma, Entomology lab Selçuk University in Konya, August 19, 2018

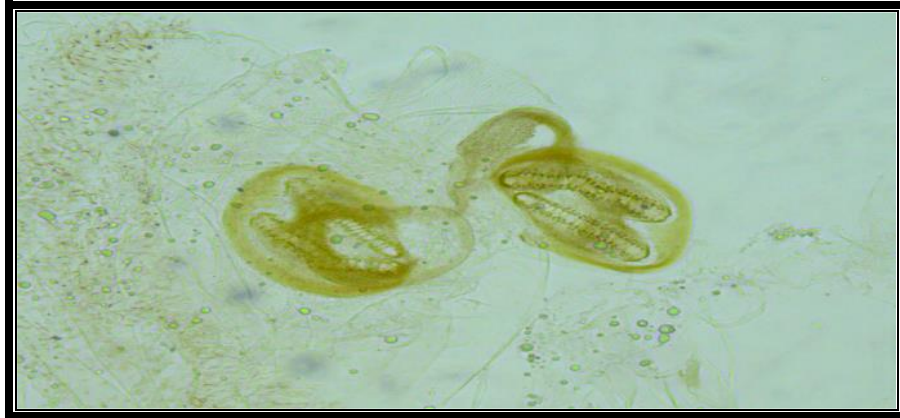


Fig. 3. *Sarcophaga argyrostoma*, second instar larva, posterior stigma, Entomology lab Selçuk University, August 19, 2018

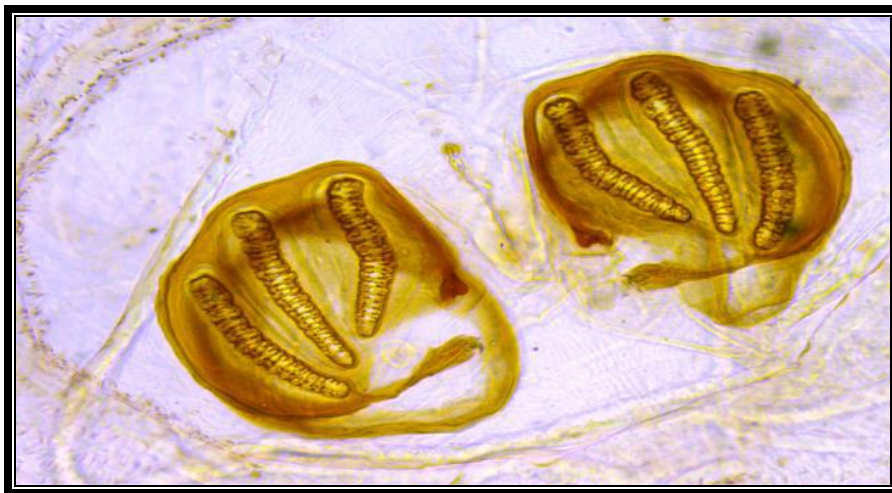


Fig. 4. *Sarcophaga argyrostoma*, third instar larva, posterior stigma, Entomology lab Selçuk University, August 19, 2018

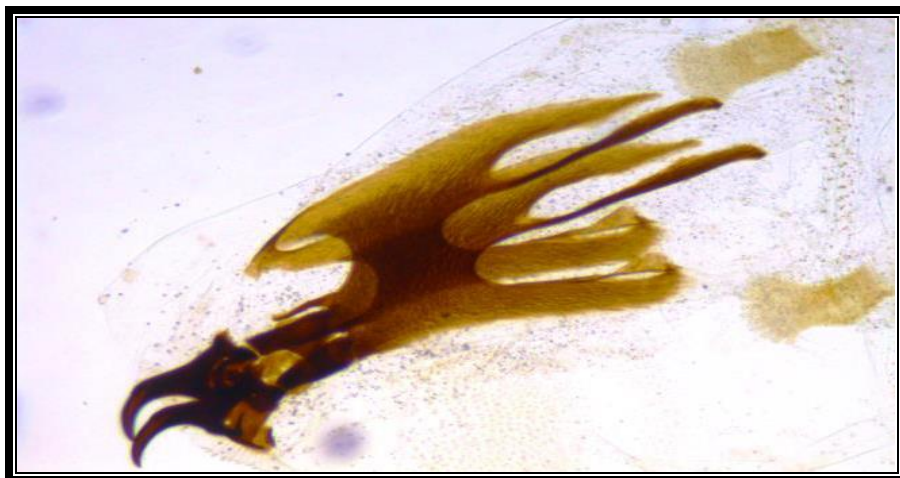

Fig. 5. *Sarcophaga argyrostoma*, second instar larva -cephaloskeleton and anterior stigma, Entomology lab Selçuk University, August 19, 2018

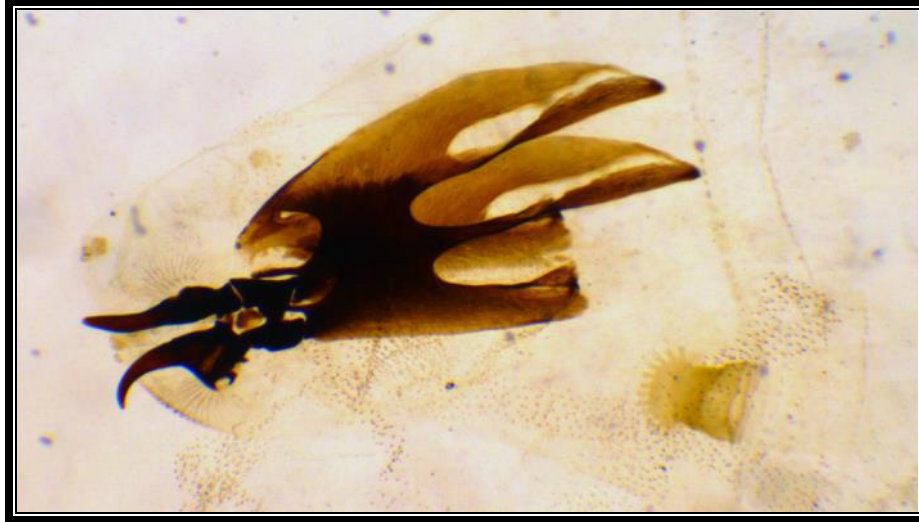

Fig. 6. *Sarcophaga argyrostoma*, third instar larva, cephaloskeleton and anterior stigma, Entomology lab Selçuk University, August 19, 2018

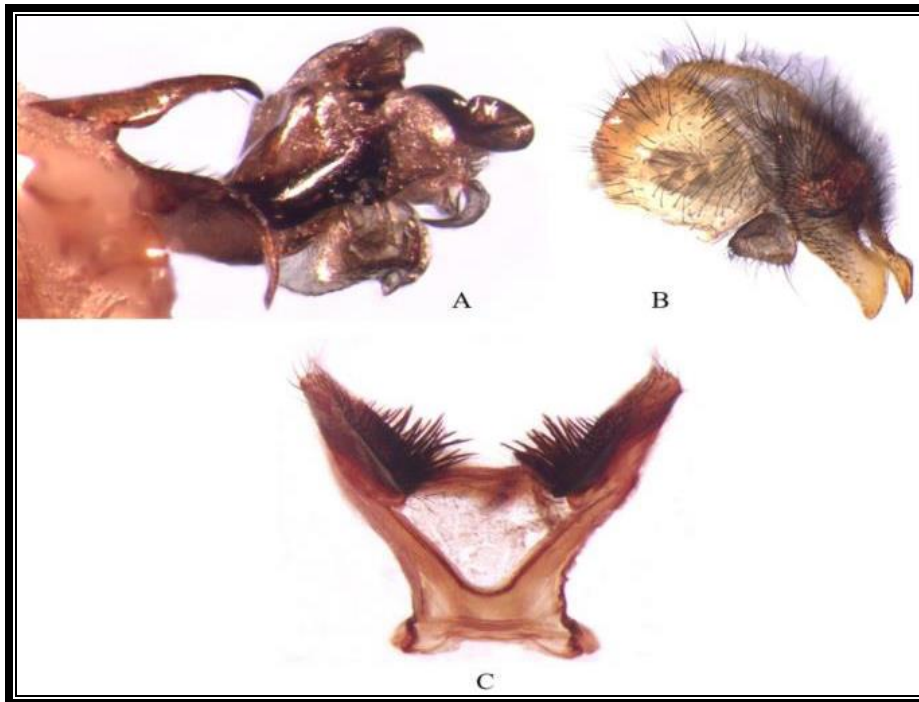


Fig. 7. *Sarcophaga argyrostoma*; A- Aedeagus lateral view B- Epandrium with cerci and surstylus C- Fifth abdominal sternite, Entomology lab at Bozok University, August 29, 2018

Discussion

It is necessary to consider two distinct subjects in the diagnosis of intestinal myiasis; the principal issue considered is the presence of fly

larvae in feces does not affirm the significance of intestinal myiasis. Most species of fly eggs or larvae that coincidentally may be intake with

nourishment cannot continue in the gastrointestinal environment. In such cases, true host infestation is never established, despite the fact, the dead larvae might be distinguished on last stool examinations. Such a circumstance is named pseudomyiasis (13). Pseudomyiasis can likewise happen when female flies lay eggs on uncovered fecal samples pot before performing laboratory processing (14). The other encounter challenge is the coexistence of concomitant infection as parasites, fungi, and viruses which may produce common related signs as cramp, gastric pain, vomiting and mislead to final intestinal myiasis diagnosis. It is important, therefore, for the symptomatic and asymptomatic patient to find live larvae more than once in stool examination and the best way is to obtain samples through sigmoidoscopy and directly from the large intestine (15).

Intestinal infestations with fly larvae have been rarely reported, especially from developing countries, however, there are such reports as Africa in Zimbabwe (Harare) (16), North America in Laramie, Wyoming (17), Taiwan, Japan, Thailand, China, India, Iran (9) and Turkey (18). Clinical presentations have been varied, including abdominal pain, nausea and vomiting, or even anal pruritus, and rectal bloodless; moreover, in some cases, it could be asymptomatic (9). To date myiasis agents associated with accidental intestinal myiasis reported as *Sarcophaga* spp., *Fannia canicularis*, *Hermetia illucens*, *Eristalis tenax*, *Muscina stabulans*, *Fannia scalaris*, *Musca domestica*, *Lucilia cuprina*, *Stomoxys calcitrans* and *Phormia regina* (15). To best of our knowledge, this is the first report of *S. argyrostoma* reported from the family Sarcophagidae in the review of the literatures revealed for intestinal myiasis. In this case, the patient was admitted to a private room. On the other hand, the patient has been under a special diet by a dietitian during the hospitalization period also the consumed food have been served under appropriate catering health conditions. In an interview with the patient, we found that she has a homemade meal [tradition-

al dish] which ingredients were starch, sugar and a kind of herbal extract was prepared out of the hospital. We discovered the remaining in her room refrigerator infested by a few tiny flies' larvae. This myiasis agent can successfully pass the gastrointestinal tract and overcome the acidic environment of the stomach and enzymatic digestion in the small intestine reported for the first time as human intestinal myiasis, caused by *S. argyrostoma* in this case. Although cited fly has reported previously in wound myiasis in an old woman in Italy (19), but has a very low occurrence rate and, does not cause any remarkable disorder for patients. Patients with immune deficiency may be more at risk for the threat of maggot's infestation (20), so in such cases, hospital standards should be more in attention. It is also necessary to monitor such patients to use only hospital meal and minimize the consumption of uncared foodstuff with outside origin. The importance of the current study is hospitalized patients, who encountered to such larvae in their stool samples, are more concerned about; moreover, for laboratory staff, to avoid misdiagnosis with some other kind of worms in the stool; furthermore, it could be attracted for health professionals to aware that this infestation may happen regardless of the socioeconomic conditions.

Conclusion

Accidental Intestinal myiasis regularly happened due to unplanned intake of dipterous larvae by contaminated food staff or water. Patients with immune deficiency may be more at risk for the threat of maggot's infestation so health care professionals should be aware for different routs of such infestations and hospital standards elevation moreover to reach an early and on time laboratory diagnosis, using Entomologist collaboration undoubtedly led to salient decrease of related morbidities not overlooked.

Acknowledgements

I take this opportunity to express my gratitude to Mr Seyed Masud Marjani for his support and lab assistance.

The authors declare that there is no conflict of interests.

References

1. Khan M, Mehboob B, Noor ULW, Mansoor N (2014) Oral myiasis: a case series of 11 patients treated at Khyber college of dentistry hospital peshawar. *Pak Oral Dent J.* 34(1): 56–60.
2. Sankari LS, Ramakrishnan K (2010) Oral myiasis caused by *Chrysomya bezziana*. *J Oral Maxillofac Pathol.* 14(1): 16–18
3. Aguilera A Cid, Regueiro A, Prieto BJ, Noya JM (1999) Intestinal myiasis caused by *Eristalis tenax*. *J Clin Microbiol.* 37(9): 3082.
4. Hall M (1991) Screwworm flies as agents of wound myiasis. *World animal review.* Available at: <http://www.fao.org/3/U4220T/u4220T07.htm>
5. Mullen GR, Durden LA (2009) *Medical and Veterinary Entomology.* Academic press. p. 792.
6. Berenji F, Hosseini-Farash BR, Marvi-Moghadam N (2015) A case of secondary ophthalmomyiasis caused by *Chrysomya bezziana* (Diptera: Calliphoridae). *J Arthropod Borne Dis.* 9(1): 125.
7. Jaenson TG (2002) Medically important parasitic arthropods (insects, ticks, and mites) of the northern Holarctic region: Parasites of the Colder Climates. Vol. 1. Taylor and Francis, London, pp. 216–254.
8. Alizadeh M, Mowlavi G, Kargar F, Nateghpour M, Akbarzadeh K, Hajenrouzali-Tehrani M (2014) A review of myiasis in Iran and a new nosocomial case from Tehran, Iran. *J Arthropod Borne Dis.* 8(2): 124.
9. Norouzi R, Manochehri A (2017) Case report of human intestinal myiasis caused by *Lucilia illustris*. *Arch Clin Infect Dis.* 12(1): e36306.
10. North DE, Matteson KL, Helgerson SD, Richards FJR, Stewart JM, Baum L, Catts EP (1987) Intestinal myiasis in a baby attending a public health clinic. *Nurse Pract.* 12(5): 60–63.
11. Szpila K, Richet R, Pape T (2015) Third instar larvae of flesh flies (Diptera: Sarcophagidae) of forensic importance-critical review of characters and key for European species. *Parasitol Res.* 114(6): 2279–2289.
12. Richet R, Blackith RM, Pape T (2011) *Sarcophaga* of France (Diptera: (Sarcophagidae): agris. Pensoft press, Bulgaria, p. 327.
13. Laarman J, Van Thiel PH (1967) A peculiar case of intestinal (pseudo) myiasis and a case of wound myiasis in the Netherlands. *Trop Geogr Med.* 19(3): 187–191.
14. Kenney M, Eveland LK, Yermakov V, Kassouny DY (1976) Two cases of enteric myiasis in man: pseudomyiasis and true intestinal myiasis. *Am J Clin Pathol.* 66(5): 786–791.
15. Francesconi F, Lupi O (2012) Myiasis. *Clin Microbiol Rev.* 25(1): 79–105.
16. Kuria SK, Villet M, Kingu H, Dhaffala A (2015) Human myiasis in rural South Africa is under-reported. *S Afr Med J.* 105(2): 129–133.
17. DeFoliart GR, Pelton E (1955) A case of human intestinal myiasis caused by *Muscina stabulans* (Fallén). *Am J Trop Med Hyg.* 4(5): 953–955.
18. Dik B, Uslu U, Işık N (2012) Myiasis in animals and human beings in Turkey. *Kafkas Univ Vet Fak Derg.* 18(1): 37–42.
19. Giangaspero A, Marangi M, Balotta A, Venturelli C, Szpila K, Di Palma A (2017) Wound Myiasis Caused by *Sarcophaga (Liopygia) Argyrostoma* (Robineau-Des-

- voidy) (Diptera: Sarcophagidae): Additional Evidences of the Morphological Identification Dilemma and Molecular Investigation. *ScientificWorldJournal*. 2017: 9064531.
20. Nagy V (2012) Unusual presentation of the urogenital myiasis caused by *Lucilia sericata* (Diptera: Calliphoridae). *Ann Agric Environ Med*. 19(4): 802–804.