

Review Article

Toxicity Mechanism of Dangerous Scorpion Stings in Iran

Rouhullah Dehghani¹, Ahmad Ghorbani², *Masoomeh Varzandeh³, Fatemeh Karami-Robati⁴

¹Social Determinants of Health (SDH) Research Center and Department of Environmental Health, Kashan University of Medical Sciences, Kashan, Iran

²Toxicology Research Center, Medical Basic Sciences Institute, Ahvaz Jundishapur University of Medical Sciences, Ahvaz, Iran

³Department of Clinical Toxicology and Poisoning, Afzalipour Hospital, Kerman University of Medical Sciences, Kerman, Iran

⁴Clinical Research Development Unit, Afzalipour Hospital, Kerman University of Medical Sciences, Kerman, Iran

Corresponding author: Dr Masoomeh Varzandeh, E-mail: Varzandeh37@gmail.com

(Received 06 Jan 2023; accepted 29 Mar 2023)

Abstract

Background: Considering the importance of scorpions and recognizing the mechanisms of toxicity caused by their medically important species in Iran and adopting the best therapeutic approach based on these mechanisms, this study was performed by reviewing the clinical manifestations of scorpion stings.

Methods: The research was conducted by searching for articles and researches in related websites (PubMed, EMBASE, Scopus, Web of Science and CINAHL) and using domestic and international authoritative journals using the keywords of scorpion, clinical manifestations, in a review method. Finally, 104 qualified sources were selected and after reviewing and criticizing these studies, the author's point of view was presented.

Results: Clinical manifestations of Scorpion sting toxicity vary due to the existence of two toxic classes of neurotoxins and cytotoxins or hemotoxins in these arthropods in Iran. The number and distribution of species with neurotoxic venom are higher than the scorpions with cytotoxic venom and are reported throughout Iran. Scorpions with cytotoxic venom are mostly widespread in south and southwest of Iran.

Conclusion: Treatment and prevention of scorpion stings in Iran and neighboring countries in the Middle East should be planned based on the mechanism of toxicity and the presence of toxic classes with neurotoxic or cytotoxic venoms.

Keywords: Poisoning; Mechanism; Hazardous; Scorpion envenomation; Iran

Introduction

Scorpion sting is one of the medical problems in tropical and subtropical countries including the Middle East, South and Central America, Africa and South Asia. It causes a wide range of complications including mild to severe local reactions and neurological, cardiovascular, and respiratory problems. In addition, in some cases it leads to death. Such condition imposes heavy costs on society economically and psychologically (1). So far, about 2231 species of scorpions have been described in 208 genera and 20 families in the world (2, 3). There are about 50 species of medical im-

portance; most of them belong to the family Butidae. The genera of *Androctonus*, *Buthus*, *Parabuthus* in Africa and *Leiurus* in the Middle East, *Tityus* in South America and *Centruroides* in Central and North America, *Mesobuthus* and *Hemiscopius* in Asia are the most dangerous scorpions in the world: (4, 5).

The situation of scorpion stings in different regions and every country is different based on socio-economic lifestyle, housing situation, health services and the species present in each geographical region. Mexico has the highest number of scorpion stings and deaths caused

by it in the world. Approximately, 281 species of scorpions have been reported in this country; 8 species among them are medically important. *Centruroides* scorpions are considered the biggest cause of death in this country. Medical importance species have been reported from 12 Mexican states (6). In Brazil, during the years 2000 to 2012, a total of 482479 cases of scorpion stings occurred, with a death rate of 0.15% (479 people). The species of genus *Tityus* are of medical importance in Brazil (7). The most important venomous and dangerous scorpions in Egypt and middle east are *Leiurus quinquestriatus*, which is a yellow scorpion and black scorpions: *Androctonus bicolor* and *A. crassicauda*. In terms of envenomation grading, most scorpion stings in middle east are moderate (8, 9). In a report, 86 species of scorpions have been identified in India. Among them, the scorpions *Mesobuthus tamulus* and *Palamneus seammer dami* have great medical importance. *Mesobuthus tamulus* and *Palamneus seammer dami* are the most frequently type of high medical importance. It has been mentioned that the fatality rate of scorpion stings in hospitalized children varies by 3–22% in India (10-12). In Iran, researchers have reported 68 species and 19 genera belonging to four families (13). Species of the genera *Androctonus* and *Hemiscopius* stings are dangerous and the deaths caused by the stings of species of these two genera have been reported in Iran, especially in the southern half of the country (13, 14). Iran has an area of 1648,000 square kilometers including 31 provinces, which are very rich in scorpion fauna. The genera *Androctonus* and *Hemiscopius* have the most lethal species, which, in addition to Iran, are widespread and deadly in Iran's neighboring countries. One of the major issues in the treatment of scorpion stings is to recognize the clinical manifestations of dangerous scorpion stings in any region. Because according to the recognition of the initial effects of the sting of the injured person in each region from the beginning to the arrival at the treatment centers, treatment

approaches can be adopted more accurately. In addition, the same treatment cannot be used to treat all species sting, in one area and for all patients. Therefore, it is not possible to use the same treatment approach for the clinical management of all species in the same area and for all people (15, 16).

Diagnosis of scorpion stings is one of the main tasks of the medical staff and physicians as well. It is necessary to know the local and systemic symptoms and their differences in different patients at high-risk areas. Considering the importance of scorpions and understanding the mechanisms of toxicity caused by medically important species and its treatment in Iran, the present study was designed to review and report the clinical manifestations of scorpion stings.

Materials and Methods

The research was conducted review method based on Keywords including scorpion sting, scorpion, systemic clinical manifestations, local pain, scorpion sting treatment, scorpion sting epidemiology. These keywords were searched in PubMed, EMBASE, Scopus, Web of Science and CINAHL databases. The study was conducted with emphasis on research sources on Iranian species. Then the articles and sources that had a detailed and technical description of scorpion stings, dangerous species of scorpions were studied, and the rest were eliminated. Regarding scorpion stings in Iran, Reputable articles were selected about Iranian scorpion stings published nationally and internationally during the last 43 years. Finally, researchers' opinions were presented about toxicity, clinical manifestations and stinging of different species of scorpions in Iran. Overall, approximately 135 sources were searched, and 104 articles were reviewed based on the set criterion.

Results

Based on the most recently studies reported in Iran, 68 species have been identified that belonged to 19 genera and four families including Buthidae, Hemiscorpiidae, Diplocentridae and Scorpionidae (13). Out of this number of scorpions, 13 stinging species have been introduced in two families and 8 genera. The stings rate of *Androctonus crassicauda*, *Mesobuthus eupeus*, *Hemiscorpius lepturus* and *Hottentotta saulcyi* have been documented from 5–45% in various reports. But, the stings of other species have been reported sporadically (Table 1) (17). Mortality rate has been reported only from the species of *Androctonus* and *Hemiscorpius* genera throughout Iran. These genera belong to two families of Buthidae and Hemiscorpiidae; their venom have neurotoxic and cytohemotoxic properties, respectively. The sting site of scorpions with neurotoxic venom is extremely painful (17–20). But the venom of the species of the genus *Hemiscorpius* is not painful primarily due to the presence of a protein called leptocin with 55 amino acids, however, it has serious fatal consequences. The sting of *Androctonus* species is very painful and deadly (21, 22). Among all the scorpion species in Iran, the sting of *A. crassicauda* and *H. lepturus* have been studied more than others in terms of frequency and dangerous complications. In recent years, more species of the genus *Hemiscorpius* have been identified, that their sting properties have not much different from *H. lepturus* and there are reported about their lethality (19, 23–26). There is a relationship between scorpion envenomation and complications of pregnancy. Risk of pregnancy in pregnant women who have stung by a scorpion depends on two factors: the location of sting (Head and neck and thorax more than extremities) and the scorpion species (*H. lepturus*). Complications has reported as preterm labor, fetal death, miscarriage, low Apgar score at 5 minute, low birth weight (27). Venom can cause abnormal uterine contractions and increase the risk of fetal death in pregnant women (28).

The family Hemiscorpiidae

Hemiscorpius lepturus

Six species of the family Hemiscorpiidae have been reported in Iran. In the southern region of Kerman Province, it is called Almask. Almask in local dialect means something that is mysterious. In this family, *H. lepturus* is at the top of the list of dangerous species in Iran. Subsequent fatal sting of *Hemiscorpius acanthocercus* has been reported in this family (Fig. 1).

Therefore, the clinical manifestations of *H. lepturus* stings have been documented (25, 26). The scorpion *H. lepturus* is one of the most important medical species in terms of clinical symptoms. The venom of this species has shown more cytohemotoxic properties in patients (29, 30). Recently, neurotoxic peptides have been identified from the venom of this species, too (31). This scorpion is observed in 15 provinces of Iran, especially in the southwest and south. The clinical manifestations of *H. lepturus* are very wide and different. These symptoms occur both locally and systemically. At the beginning, the local manifestation is slight pain and can be compared to the insertion of a needle tip with a gauge of 27–30 and a length of 1–2mm inside the skin (32). The reason for the lack of pain is that the venom of this scorpion has an analgesic protein called leptocin (33). Due to the slow absorption of the venom, local or systemic symptoms in the victims are not predictable. Unlike other scorpion stings, it is possible to have no symptoms at the beginning of the injury; clinical manifestations may be observed gradually or together in the patient for 2 to 7 days. Many patients, especially adults, have a normal general condition for the first 24 to 72 hours; it is only after this period that their status may change (29, 32, 34). Abnormal nervous behaviors, occult hemolysis, severe hemolysis, fever, sweating, chills, tachycardia, lethargy, anorexia, petechiae and skin rashes, hypotension and paleness

are prominent symptoms of *H. lepturus* victims. Even after a long time, after being stung, patients suffer long-term from mental disorders, such as increased aggressiveness, irritability, emotional disorders, and depression (24, 29, 32, 35, 36). In some cases, extensive necrosis occurs at the sting site. These wounds are sometimes active for 5–6 months and cause extensive necrosis, which leaves a large scar (24, 37, 38). Clinical skin manifestations of *H. lepturus* envenomation are very similar to brown spiders. The same mechanism of molecular evolution occurs in both *H. lepturus* and the *Loxosceles reclusa* or American brown spider. Phospholipase is responsible for the lethality and toxicity of both, such that *Hemiscorpius lepturus* Recombinant Phospholipase D1 (HI-RecPLD1) (The active form of PLD) has been identified as the lethal toxin in *H. lepturus* venom (39). It has also been shown that *H. lepturus* cause serious ulcers, that can resemble third-degree burns with blisters and necrosis (24, 25, 29). The skin manifestations of several Gadim scorpion victims are shown in Fig. 2.

Kidney failure in patients with *H. lepturus* sting has always occurred after hemoglobinuria. These clinical manifestations can be significantly important in predicting the possibility of kidney failure: fever, jaundice, and dark urine in the first 24 hours, extensive sting site inflammation, generalized erythema, consciousness alternation, stings on the trunk and face, leukocytosis, thrombocytopenia, severe anemia and decrease in urine specific gravity (36, 40–42). Plasmapheresis was performed in patients who stung by severely envenomation of *H. lepturus* and clinical manifestation of disseminated intravascular coagulation (DIC) and the results showed that Plasmapheresis can prevent death and help patients recovery (43).

The family Buthidae

Androctonus crassicauda

Androctonus crassicauda is one of the most dangerous species in Iran (Fig. 3). Mortality cases attributed to its sting has been reported

more in the southern half of Iran than elsewhere (44, 45). This species has caused deadly stings in the Middle East, North Africa and Egypt, Turkey, Iraq, Saudi Arabia as well (46–49). Symptoms of the sting include pain and burning at the site. The general symptoms such as agitation, restlessness, dizziness, anesthesia, drowsiness, miosis, nystagmus, increased secretion of exocrine glands including sweat glands, lacrimal glands, salivary glands, increased frequency of defecation and urination may follow (19, 32). Clinical symptoms such as severe pain, numbness of the stung limb, abdominal pain, excessive rhinorrhea and hyper salivation, foamy vomiting have been observed in deceased victims before death and in their general examinations these signs have been detected: tachycardia, tachypnea, filiform pulse and decreased tendon reflexes, hypothermia in the range of 35 degrees, cold and cyanotic extremities, Hypotension to the systolic pressure 4. In the following hours, severe thirst, bloody vomiting or hematemesis and melena, semi-consciousness, coma, and death have been occurred. Death in sensitive people have been occurred 9 to 36 hours after the sting and it has happened more in children and less in adults. In some victims have been reported; increase in white blood cells (leukocytosis) to about 20,000, increase in granulocytes to more than 90%, and a decrease in lymphocytes to about 10%. In some of them have been seen; glucose, protein and blood in the urine (50–52).

Mesobuthus eupeus

The *Mesobuthus eupeus* sting cause severe to moderate pain around the sting site that disappears within one to several hours. When scorpion sting occurs, the pain is the only reason that the patient to refer to the physician and ask for medical help. The sting pain of this scorpion is gradually reduced. In some patients, some constitutional symptoms such as thirst, dry mouth, dizziness, nausea, sweating, headache, restlessness may occur due to stress caused by fear. The venom of this scorpion influences the

nervous system; it triggers sympathetic and parasympathetic responses (15, 23, 32). Some of these symptoms may be caused by the stimulation of one of these systems. These sympathetic and parasympathetic symptoms disappear when the patient calms down and the pain subsides. No sign is visible at the sting site unless the patient or people around him manipulate it by squeezing or other acts such as cutting the tissue, which occasionally leads to ecchymosis, redness, and swelling, these local skin lesions should not be considered as signs of the scorpion sting (51, 52).

Odontobuthus doriae

The sting of *Odontobuthus doriae* is somewhat similar to that of *Androctonus crassicauda*. This arthropod lives in virgin natural habitats because it is a digger and nest maker. Therefore, despite the fact that *O. doriae* has a high geographical spread in Iran, rarely its sting occurs (53). Severe and excruciating pain spreads immediately from the sting site. Local anesthetics have no effect on reducing pain. Clinical manifestations other than pain includes restlessness and severe muscle contractions. Prescribing analgesics and corticosteroid anti-inflammatory drugs have no effect in reducing pain or improving clinical complications within 15 hours after the sting. In healthy adult victims, the pain gradually subsides after about 25 hours. Pulmonary edema has been reported in stung people (18, 23, 54, 55).

Compsobuthus matthiesseni

Presently, 7 species of *Compsobuthus* have been identified in Iran. Only the sting of two species, *C. matthiesseni* and *C. persicus*, have been reported (13). Pain from *Compsobuthus* species stings in some adults lasts up to about three hours and gradually decreases and disappears completely, however, the patients experience dizziness, nausea, and lethargy for up to two days after the sting. The body becomes lethargic, and the person is unable to perform

normal activities. In healthy adults, systemic manifestations of toxicity resolve more rapidly after a maximum of 2 to 3 days. Urinalysis tests and CBC, ESR, SGPT, SGOT, BUN and creatinine levels reported normal. Normal E.K.G was reported in all patients (26, 56, 57).

Apistobuthus pterygosercus

The sting of *Apistobuthus pterygosercus* has been reported sporadically. Some of the clinical complications of this scorpion sting includes miosis, runny nose and watery eyes, hypersalivation, shortness of breath with wheezing, abdominal distension and attack or anxiety that are somewhat similar to those caused by scorpion of *A. crassicauda* (58). There were not any proprietary reports on stings by other species such as *Buthotus saulcyi*, *Mesobuthus (Olivierus) caucasicus*, *Orthochirus scrobiculosus*, *Hottentotta jayakari*, *Hottentotta schach*. These species all belong to the Butidae family; therefore, their stings primarily cause severe pain in victims. These species are relatively widely distributed throughout Iran (23, 25, 38).



Fig. 1. Photo of four live *Hemiscorpius lepturus* (Hemiscorpiidae) in Iran (photo was prepared by Dr Rouhullah Dehghani)

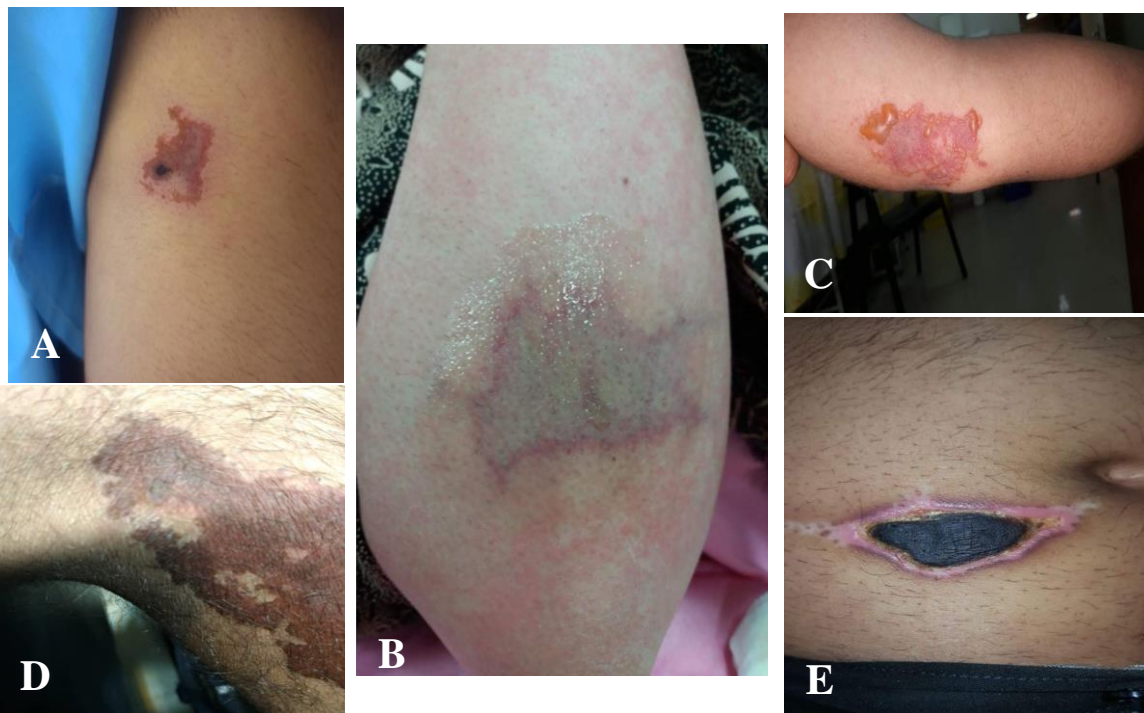


Fig. 2. (A) Skin clinical manifestation at the sting site caused by the *Hemiscorpius lepturus* sting two days post sting, (B) The third day after the *Hemiscorpius lepturus* sting, (C) Two to four days after *Hemiscorpius lepturus* sting, (D) Three to five days after *Hemiscorpius lepturus* sting, (E) One month after *Hemiscorpius lepturus* sting (All photos were prepared by Dr Ahmad Ghorbani)

Table 1. Scorpion sting agents in Iran based on family, genus and species

Family	Genus	Species	References
Buthidae	<i>Mesobuthus</i>	<i>Mesobuthus eupeus</i>	17, 23, 32
		<i>Mesobuthus(Olivierus) caucasicus</i>	17, 32
	<i>Compsobuthus</i>	<i>Compsobuthus matthiesseni</i>	32
		<i>Compsobuthus persicus</i>	25
	<i>Apistobuthus</i>	<i>Apistobuthus pterygocercus</i>	17
	<i>Odontobuthus</i>	<i>Odontobuthus doriae</i>	18, 23
	<i>Orthochirus</i>	<i>Orthochirus scrobiculosus</i>	23
	<i>Androctonus</i>	<i>Androctonus crassicauda</i>	19
	Hottentotta	<i>Hottentotta jayakari</i>	23
		<i>Hottentotta schach</i>	23
<i>Hottentotta saulcyi</i>		23	
Hemiscorpiidae	<i>Hemiscorpius</i>	<i>Hemiscorpius lepturus</i>	29, 30, 31
		<i>Hemiscorpius acanthocercus</i>	26
2	8	13	

**Fig. 3.** Photo of a *Androctonus crassicauda* (Buthidae) in Iran (photo was prepared by Dr Rouhullah Dehghani)

Discussion

Scorpion venom is a heterogeneous compound that is soluble in water with antigenic properties. This heterogeneity causes various reactions in scorpion sting victims. Phylogenetically, close species produce more similar symptoms in patients. The differences between the amino acid sequences of each venom cause differences in action and immunology; any changes in the amino acid sequence causes a change in the action and immunology of the venom (59, 60). Scorpion venom is composed of neurotoxins, cardiotoxins, nephrotoxins, hematotoxins,

and phosphodiesterase, phospholipases, hyaluronidases, and histamine, serotonin, tryptophan and cytokine release agent. Most dangerous species of scorpions in the world have neurotoxic venom, that effect on ion channels. Low molecular weight neurotoxin is responsible for neurological, muscular, and cardiac problems and changes in ion channel permeability (61, 62). Long-chain neurotoxin polypeptides cause voltage-dependent opening or closing of sodium channels (63–65). In some scorpion's venom, exist calcium channel modulating peptides can

cause contractile paralysis due to increasing of intracellular Ca^{2+} level (66). Therefore, scorpion venom causes prolongation and repetition of the nerve impulses in the sympathetic and parasympathetic nerves. As a result, the repetition of this message stimulates the autonomic nerve and overstimulates the muscular nerves. This causes the non-transmission of the neural impulses normally (67). The stability of the neurotoxin is due to the presence of disulfide bridges that compress the neurotoxin in a compact three-dimensional structure. Because of this, the neurotoxin is resistant to pH and temperature changes. Long chain neurotoxin of *A. crassicauda* venom is stable due to these disulfide bridges (68). Toxicity and severity of complications and its duration depends on various factors. These factors include: scorpion species, scorpion age, size, type of feeding, number of stings and amount of venom injected, sting depth, venom composition and sting site (on the head and neck and proximity to sensitive areas cause faster absorption and reach the central nervous system and occurs rapid symptoms) (69, 70). The victim's physiological response (reaction) depends on the venom properties, age, weight and treatment efficacy. The most common symptoms of a scorpion sting are nausea, vomiting, nystagmus, mydriasis, hypersalivation, dysphagia and restlessness. Death usually occurs due to causes such as: cardiovascular failure, respiratory failure, anaphylactic shock, bronchoconstriction, bronchorrhea, pharyngeal secretions, diaphragmatic paralysis and multiorgan failure (47, 60, 71, 72). The clinical manifestations have been observed in children with the same adult symptoms but more severely and over a longer period. Restlessness is more common than any other diseases. Localized pain, hyperemia, vomiting, sweating, restlessness, tachycardia, and tachypnea have been reported in children. Research reports showed that symptoms of scorpion sting in a child includes persistent crying, uncontrollable limb jumping, and facial muscle twitching that gives it a scary appearance (73–76).

The *H. lepturus* sting is an exception among the important species in terms of clinical signs. In the venom of *H. lepturus* protease and metalloproteinase has been derived (77). These enzymes can inhibit platelet aggregation and stimulate cytokine production (78, 79). Altogether, these effects facilitate the diffusion of scorpion venom toxins via the degradation of matrix proteins. The clinical manifestations of the sting of this species are too wide and varied. *Hemiscorpius lepturus* sting initially presents as a slight itching without any or little pain around the stinging site. In addition to the presence of leptocin in the venom (33), lack of pain or mildness of the degree of pain sensation when a person is stung can be due to the small stinger of the scorpion and its low penetration power into the skin layers. A few days later, the sting site may become swollen and painful. This symptom is contrary to the sting of Butidae family scorpions in Iran with neurotoxic venom (23–25). Over time, if the venom penetrates the dermis and adjacent tissues, causing cellulite and severe inflammation. At that time, severe pain is felt around the sting, followed by cellulite. This inflammation and cellulite, which gradually increases in diameter, may cover an area as large as 30cm in diameter and eventually develop into gangrene and ulcers. Occasionally small and large blisters develop around the sting site that do not have a good prognosis and may lead to hemolysis or large and deep wounds. Edema, cellulite, blisters, gangrene and Ulcers are signs of Cytotoxicity of *H. lepturus* venom (29). Due to the softness of the skin and the thinness of the tissue in children, *H. lepturus* sting leads to severe swelling and inflammation that may spread wider. Neck, face and trunk stings in both children and adult patients usually lead to more cellulite and inflammation. They have more clinical symptoms, both locally and systemically (24, 29, 32). *Hemiscorpius lepturus* venom causes symptoms such as dry mouth, dizziness, lethargy and anorexia; it has a toxic effect on the central nervous system, blood cir-

culatation and red blood cells. *Hemiscorpius lepturus* venom has a significant effect on the extensive change of white blood cells and leads to erythematous rashes and hemorrhagic petechiae on the skin (42, 76, 80). Venom of *H. lepturus* has a slow absorption rate, due to its properties; next local or systemic symptoms in the victims are not predictable. Unlike other venoms, it may have no symptoms for 2 to 7 days at the beginning of the injury. Therefore, it can be concluded that the venom of *Gadim* or *H. lepturus* has a long life, even up to a week in the body. Many patients, especially adult, have a normal general condition for the first 24 to 72 hours; it is only after this period that their condition may change (29, 32, 34). In some cases, extensive necrosis occurs at the site of the *Gadim* sting. In some cases, these lesions are active for 5–6 months and cause extensive necrosis, which leaves a large scar (24, 37, 38). Studies in laboratory animals have shown that the venom of this scorpion causes necrosis and scarring of the skin (76, 81).

Kidney failure in victims of *Gadim* has been documented in research articles in Iran. Decrease of urine specific gravity before renal failure is one of the findings that may be important in predicting patients with renal failure (36, 40–42). Studies have shown that kidney failure and nephropathy due to the sting of other species have been reported in various countries such as Pakistan, Brazil, Algeria, Bosnia and Sri Lanka (82–89). Studies in laboratory animals also confirm renal failure due to the venom of *H. lepturus* (90–93).

The venom of scorpions has various components that may be used to treat infectious diseases such as AIDS, malaria, toxoplasmosis, hydatid and cancer. Also, proteins with pain-reducing properties have been extracted from them; this has been examined by some researchers (94–102).

Conclusion

The stings of the species of *Hemiscorpius*,

Odontobuthus and *A. crassicauda* are fatal in Iran. The rest of the species are mildly important. Treatment and prevention of scorpion stings in Iran and neighboring countries in the Middle East should be planned based on the mechanism of toxicity and the presence of toxic classes with neurotoxic and cytohemotoxic venoms. One of the major issues in the treatment of scorpion stings is the diagnosis of clinical manifestations of dangerous species in each region. Based on this knowledge, the initial symptoms in the injured person in medical centers, recovery and treatment strategies may be adopted more accurately. Recognizing the stings of different species of scorpions is one of the main tasks of medical staff, especially physicians. It is necessary to know the local and systemic symptoms and their differences in different people in high-risk areas.

Acknowledgments

Authors are grateful to participants and staff of facilities for their logistic support.

Ethical considerations

This study was approved by the research ethics committee of Kerman University of Medical Sciences and the ethical code number is IR.KMU.AH.REC.1400.380.

Conflict of interest statement

The authors declare there is no conflict of interests.

References

1. Isbister GK, Bawaskar HS (2014) Scorpion envenomation. *N Engl J Med.* 371(5): 457–463.
2. Prendini L (2011) Order Scorpiones CL Koch, 1850. In: Zhang, Z.-Q.(Ed.) *Animal biodiversity: An outline of higher-*

- level classification and survey of taxonomic richness. *Zootaxa*. 3148(1): 115–117.
3. Rein-Ove J (2014) Scorpion Files [Internet]. Norwegian University of Science and Technology, Trondheim. Available at: <http://www.ntnu.no/ub/scorpion-files>.
 4. Santos MS, Silva CG, Neto BS, Júnior CRG, Lopes VH, Júnior AGT, Bezerra DA, Luna JV, Cordeiro JB, Júnior JG (2016) Clinical and epidemiological aspects of scorpionism in the world: a systematic review. *Wilderness Environ Med*. 27(4): 504–518.
 5. Marks CJ, Muller GJ, Sachno D, Reuter H, Wium CA, Du Plessis CE, Van Hoving DJ (2019) The epidemiology and severity of scorpion envenoming in South Africa as managed by the Tygerberg Poisons Information Centre over a 10 year period. *Afr J Emerg Med*. 9(1): 21–24.
 6. Santibáñez-López CE, Francke OF, Ureta C, Possani LD (2015) Scorpions from Mexico: From species diversity to venom complexity. *Toxins (Basel)*. 8(1): 2.
 7. Pucca MB, Oliveira FN, Schwartz EF, Arantes EC, Lira-da-Silva RM (2015) Scorpionism and Dangerous Species of Brazil. In: Gopalakrishnakone P, Possani L, F Schwartz E, Rodríguez de la Vega R (eds) *Scorpion Venoms*. *Toxicology*, vol 4. Springer, Dordrecht.
 8. Bentur Y, Taitelman U, Aloufy A (2003) Evaluation of scorpion stings: the poison center perspective. *Vet Hum Toxicol*. 45(2): 108–111.
 9. Abd El F, El Shehaby D, Elghazally S, Hetta H (2019) Toxicological and epidemiological studies of scorpion sting cases and morphological characterization of scorpions (*Leiurus quin questriatus* and *Androctonus crassicauda*) in Luxor. *Egypt Toxicol Rep*. 6: 329–335.
 10. Yadav R, Alim M, Yadav Y, Singh D, Kumar A (2020) Retrospective Study of Children with Scorpion Envenomation in a Tertiary Care Center of North India. *Asia Pac J Med Toxicol*. 9(3): 91–96.
 11. Bawaskar HS, Bawaskar PH (2011) Efficacy and safety of scorpion antivenom plus prazosin compared with prazosin alone for venomous scorpion (*Mesobuthus tamulus*) sting: randomised open label clinical trial. *BMJ*. 342: c7136.
 12. Mahadevan S (2000) Scorpion sting. *Indian Pediatr*. 37(5): 504–514.
 13. Barahoei H, Navidpour S, Aliabadian M, Siahsarvie R, Mirshamsi O (2020) Scorpions of Iran (Arachnida: Scorpiones): Annotated checklist, DELTA database and identification key. *J Insect Biodivers Syst*. 6(4): 375–474.
 14. Mohammadi Bavani M, Rafinejad J, Hanafi-Bojd AA, Oshaghi MA, Navidpour S, Dabiri F, Badakhshan M, Ghorbani E, Bagheri M (2017) Spatial distribution of medically important scorpions in north west of Iran. *J Arthropod Borne Dis*. 11(3): 371–382.
 15. Ghorbani A, Mansouri B, Baradaran M (2021) Effects of climate variables on the incidence of scorpion stings in Iran for five years. *J Venom Anim Toxins Incl Trop Dis*. 27:e20200110.
 16. Nejati J, Mozafari E, Saghafipour A, Kiyani M (2014) Scorpion fauna and epidemiological aspects of scorpionism in south-eastern Iran. *Asian Pac J Trop Biomed*. 4: S217–S21.
 17. Dehghani R, Charkhloo E, Seyyedi-Bidgoli N, Chimehi E, Ghavami-Ghameshlo M (2018) A review on scorpionism in Iran. *J Arthropod Borne Dis*. 12(4): 325–333.
 18. Vatanpour H, Jalali A, Rowan EG, Rahim F (2013) Effects of *Odontobuthus doriae* scorpion venom on mouse sciatic nerve. *Iran J Pharm Res*. 12(Suppl): 145–151.
 19. Radmanesh M (1990) *Androctonus crassicauda* sting and its clinical study in Iran. *J Trop Med Hyg*. 93(5): 323–326.
 20. Bawaskar H, Bawaskar P (2012) Scorpion sting: update. *J Assoc Physicians India*. 60: 46–55.

21. Sanaei-Zadeh H (2017) Painless stings of yellow Iranian scorpions. *Iran Red Crescent Med J.* 19(4): e42645.
22. Kassiri H, Dehghani R, Kaviani M, Dehghani M, Kasiri M (2020) First report of *Hottentotta schach* (Arachnida: Scorpionida: Buthidae) as a new record from Isfahan Province, Central Iran. *J Entomol Res.* 44(1): 153–156.
23. Dehghani R, Fathi B (2012) Scorpion sting in Iran: a review. *Toxicon.* 60(5): 919–933.
24. Radmanesh M (1990) Clinical study of *Hemiscorpion lepturus* in Iran. *J Trop Med Hyg.* 93(5): 327–332.
25. Dehghani R, Kamiabi F, Mohammadi M (2018) Scorpionism by *Hemiscorpius* spp. in Iran: a review. *J Venom Anim Toxins Incl Trop Dis.* 24: 8.
26. Shahi M, Rafinejad J, Az-Khosravi L, Moosavy SH (2015) First report of death due to *Hemiscorpius acanthocercus* envenomation in Iran: Case report. *Electron Physician.* 7(5): 1234.
27. Najafian M, Ghorbani A, Zargar M, Baradaran M, Baradaran N (2020) Scorpion stings in pregnancy: an analysis of outcomes in 66 envenomed pregnant patients in Iran. *J Venom Anim Toxins Incl Trop Dis.* 26: e20190039.
28. Ben Nasr H, Hammami T, Sahnoun Z, Rebai T, Bouaziz M, Kassis M, Zeghal K (2007) Scorpion envenomation symptoms in pregnant women. *J Venom Anim Toxins Incl Trop Dis.* 13: 94–102.
29. Radmanesh M (1998) Cutaneous manifestations of the *Hemiscorpius lepturus* sting: a clinical study. *Int J Dermatol.* 37(7): 500–507.
30. Pipelzadeh MH, Dezfulian AR, Jalali MT, Mansouri AK (2006) In vitro and in vivo studies on some toxic effects of the venom from *Hemiscorpius lepturus* scorpion. *Toxicon.* 48(1): 93–103.
31. Maleki M, Dounighi NM (2020) Purification and characterization of a novel type of neurotoxic peptides from the venom of the Iranian scorpion *Hemiscorpius lepturus*. *Iran J Basic Med Sci.* 23(2): 195–201.
32. Radmanesh M (1990) Surveying scorpion sting in general. *Darou va Darman Journal.* 8: 26–30.
33. Bagheri Ziari S, Shahbazzadeh D, Sardari S, Sabatier J-M, Pooshang Bagheri K (2021) Discovery of a new analgesic peptide, leptucin, from the Iranian scorpion, *Hemiscorpius lepturus*. *Molecules.* 26(9): 2580.
34. Mirakabbadi AZ, Zolfagharian H, Hedayat A, Jalali A (2007) Clinical and biochemical manifestation produced by scorpion (*Hemiscorpius lepturus*) venom in experimental animals. *J Venom Anim Toxins Incl Trop Dis.* 13: 758–765.
35. Rahmani A, Jalali A (2012) Symptom patterns in adult patients stung by scorpions with emphasis on coagulopathy and hemoglobinuria. *J Venom Anim Toxins Incl Trop Dis.* 18: 427–431.
36. Valavi E, Ansari MA (2008) Hemolytic uremic syndrome following *Hemiscorpius lepturus* (scorpion) sting. *Indian J Nephrol.* 18(4): 166–168.
37. Hedayat B, Rahmani AH, Matinrad M, Nazari P (2018) The Epidemiologic and Clinical Study on *Hemiscorpius Lepturus* (Gadim) Envenomation with Focus on Clinical Manifestations, Prognosis Factors, and Outcomes. *Asia Pac J Med Toxicol.* 7(4): 97–100.
38. Dehghani R, Arani MG (2015) Scorpion sting prevention and treatment in ancient Iran. *J Tradit Complement Med.* 5(2): 75–80.
39. Torabi E, Behdani M, Hosseininejad Chafi M, Moazzami R, Sabatier J-M, Khalaj V, Shahbazzadeh D, Pooshang Bagheri K (2017) Characteristics and lethality of a novel recombinant dermonecrotic venom phospholipase D from *Hemiscorpius lepturus*. *Toxins.* 9(3): 102.

40. Mashak Z, Nemat R, Mahboobian B (2000) Epidemiologic Survey Of Scorpion Sting In Abozar Hospital, Ahwaz Province, Iran Between 1989–1990. *Hakim*. 3(3): 215–223.
41. Malhotra K, Chadha J, Mirdehghan M, Tandon H (1978) Acute renal failure following scorpion sting. *Am J Trop Med Hyg*. 27(3): 623–626.
42. Jalali A, Pipelzadeh MH, Sayedian R, Rowan E (2010) A review of epidemiological, clinical and in vitro physiological studies of envenomation by the scorpion *Hemiscorpius lepturus* (Hemiscorpiidae) in Iran. *Toxicon*. 55(2–3): 173–179.
43. Mostafazadeh B, Gorbani A, Mogaddaspour M, Khoddami Vishteh HR (2017) The effect of plasmapheresis on treating disseminated intravascular coagulation (DIC) caused by a *Hemiscorpius lepturus* (Gadim) sting. *Clin Toxicol*. 55(8): 902–907.
44. Rafizadeh S, Rafinejad J, Rassi Y (2013) Epidemiology of scorpionism in Iran during 2009. *J Arthropod Borne Dis*. 7(1): 66–70.
45. Firoozfar F, Saghafipour A, Jesri N (2019) Scorpions and their human mortality report in Iran: a review article. *Iran J Public Health*. 48(12): 2140–2153.
46. Alhamoud MA, Al Fehaid MS, Alhamoud MA, Alzoayed MH, Alkhalifah AA, Menezes RG (2021) Scorpion Stings in Saudi Arabia: An Overview. *Acta Biomed*. 92(4): e2021273.
47. Feola A, Perrone MA, Piscopo A, Casella F, Della Pietra B, Di Mizio G (2020) Autopsy Findings in Case of Fatal Scorpion Sting: A Systematic Review of the Literature. *Healthcare (Basel)*. 8(3): 325.
48. Ward MJ, Ellsworth SA, Nystrom GS (2018) A global accounting of medically significant scorpions: Epidemiology, major toxins, and comparative resources in harmless counterparts. *Toxicon*. 151: 137–155.
49. Caliskan F, García BI, Coronas FI, Batista CV, Zamudio FZ, Possani LD (2006) Characterization of venom components from the scorpion *Androctonus crassicauda* of Turkey: peptides and genes. *Toxicon*. 48(1): 12–22.
50. Rahimi M, Sh Sh, Mirzaei Nasab R, Soltaninejad K (2020) Scorpion Stings in Tehran Province, Iran: A Seven-year Hospital-based Study. *Int J Med Toxicol Forensic Med*. 10(4): 30274.
51. Dehghani R, Khamechian T, Dehghani A, Limoe M, Limoe M, Hossini H (2020) Investigation of the Behavioral and Clinical Effects of Black Scorpion Venom in Albino Rats. *Iran J Toxicol*. 14(3): 165–170.
52. Kassiri H, Dehghani R, Doostifar K, Saberi H, Dehghani M (2020) Micro habitat of *Androctonus crassicauda* (Arachnida: Scorpionida: Buthidae) in Isfahan, Khuzestan and Kerman Provinces, Iran. *J Entomol Res*. 44(3): 489–494.
53. Dehghani R, Kassiri H (2017) Geographical distribution of scorpion *Odontobuthus doriae* in Isfahan Province, central Iran. *J Arthropod Borne Dis*. 11(3): 433–440.
54. Razi E, Malekanrad E (2008) Asymmetric pulmonary edema after scorpion sting: a case report. *Rev Inst Med Trop Sao Paulo*. 50: 347–350.
55. Jalali A, Vatanpour H, Hosseinasab Z, Rowan EG, Harvey AL (2007) The effect of the venom of the yellow Iranian scorpion *Odontobuthus doriae* on skeletal muscle preparations in vitro. *Toxicon*. 50(8): 1019–1026.
56. Dehghani R, Djadid ND, Shahbazzadeh D, Bigdelli S (2009) Introducing *Compsobothus matthiesseni* (Birula, 1905) scorpion as one of the major stinging scorpions in Khuzestan, Iran. *Toxicon*. 54(3): 272–275.

57. Farzanpey R (1994) Scorpion sting and the fallowing of it. *Pajouhesh va Sazandegi*. 259(3): 123–125.
58. Radmanesh M, Shaffiee S (1989) Clinical study of *Apistobuthus pterygocercus* sting. *Journal of Daru and Darman*. 6(63): 9–10.
59. Petricevich VL (2010) Scorpion venom and the inflammatory response. *Mediators Inflamm*. 2010: 903295.
60. Nencioni ALA, Beraldo Neto E, Freitas LAd, Dorce VAC (2018) Effects of Brazilian scorpion venoms on the central nervous system. *J Venom Anim Toxins Incl Trop Dis*. 24: 3.
61. Horta CCR, Magalhaes BdF, Oliveira-Mendes BBR, Carmo AOd, Duarte CG, Felicori LF, Machado-de-Avila RA, Chavez-Olortegui C, Kalapothakis E (2014) Molecular, immunological, and biological characterization of *Tityus serrulatus* venom hyaluronidase: new insights into its role in envenomation. *PLoS Negl Trop Dis*. 8(2): e2693.
62. Quintero-Hernández V, Jiménez-Vargas J, Gurrola G, Valdivia H, Possani L (2013) Scorpion venom components that affect ion-channels function. *Toxicon*. 76: 328–342.
63. Al-Asmari AK, Kunnathodi F, Al Saadon K, Idris MM (2016) Elemental analysis of scorpion venoms. *J Venom Res*. 7: 16–20.
64. Israel MR, Tay B, Deuis JR, Vetter I (2017) Sodium channels and venom peptide pharmacology. *Adv Pharmacol*. 79: 67–116.
65. Stevens M, Peigneur S, Tytgat J (2011) Neurotoxins and their binding areas on voltage-gated sodium channels. *Front Pharmacol*. 2: 71.
66. Ahmadi S, Knerr J, Argemi L, Bordon K, Pucca M, Cerni F, Arantes E, Çaliskan F, Laustsen A (2020) Scorpion venom: detriments and benefits. *Biomedicines*. 8(5): 118.
67. Bosmans F, Tytgat J (2007) Voltage-gated sodium channel modulation by scorpion α -toxins. *Toxicon*. 49(2): 142–158.
68. Jolodar A (2019) Molecular Characterization of a Three-disulfide Bridges Beta-like Neurotoxin from *Androctonus crassicauda* Scorpion Venom. *Arch Razi Inst*. 74(2): 135–142.
69. Bawaskar H, Bawaskar P (1998) Indian red scorpion envenoming. *Indian J Pediatr*. 65(3): 383–391.
70. Bahloul M, Chaari A, Dammak H, Samet M, Chtara K, Chelly H, Hamida CB, Kallel H, Bouaziz M (2013) Pulmonary edema following scorpion envenomation: mechanisms, clinical manifestations, diagnosis and treatment. *Int J Cardiol*. 162(2): 86–91.
71. Castillo A, Attaluri P (2018) Acute respiratory failure following scorpion stings: Anaphylaxis or severe systemic envenomation? *The Southwest Respiratory and Critical Care Chronicles*. 6(22): 47–50.
72. Dutto M, Dutto L, Bertero M, Goyffon M (2012) Stings from *Euscorpis flavicaudis* (De Geer, 1778) (Scorpiones, Euscorpidae) during pregnancy: a clinical case report. *J Venom Anim Toxins Incl Trop Dis*. 18: 462–466.
73. Abourazzak S, Achour S, El Arqam L, Atmani S, Chaouki S, Semlali I, Soulaymani Bencheikh R, Bouharrou A, Hida M (2009) Epidemiological and clinical characteristics of scorpion stings in children in Fez, Morocco. *J Venom Anim Toxins Incl Trop Dis*. 15: 255–267.
74. Vazirianzadeh B, Farhadpour F, Hosseinzadeh M, Zarean M, Moravvej S (2012) An epidemiological and clinical study on scorpionism in hospitalized children in Khuzestan, Iran. *J Arthropod Borne Dis*. 6(1): 62–69.
75. Bawaskar H, Bawaskar P (1991) Cardiovascular manifestations of severe scorpion sting in India (review of 34 children). *Ann Trop Paediatr*. 11(4): 381–387.
76. Ghafourian M, Ganjalikhanhakemi N, Hemmati AA, Dehghani R, Kooti W (2016) The effect of *Hemiscorpius lepturus* (Scor-

- pionida: Hemiscorpiidae) venom on leukocytes and the leukocyte subgroups in peripheral blood of rat. *J Arthropod Borne Dis*. 10(2): 159–167.
77. Kazemi-Lomedasht F, Khalaj V, Bagheri KP, Behdani M, Shahbazzadeh D (2017) The first report on transcriptome analysis of the venom gland of Iranian scorpion, *Hemiscorpius lepturus*. *Toxicon*. 125: 123–130.
 78. Cordeiro FA, Coutinho BM, Wiesel GA, Bordon KdCF, Bregge-Silva C, Rosa-Garzon NG, Cabral H, Ueberheide B, Arantes EC (2018) Purification and enzymatic characterization of a novel metalloprotease from *Lachesis muta rhombata* snake venom. *J Venom Anim Toxins Incl Trop Dis*. 24: 32.
 79. Gutierrez JM, Rucavado A (2000) Snake venom metalloproteinases: their role in the pathogenesis of local tissue damage. *Biochimie*. 82(9–10): 841–850.
 80. Pipelzadeh MH, Jalali A, Taraz M, Pourabbas R, Zaremirakabadi A (2007) An epidemiological and a clinical study on scorpionism by the Iranian scorpion *Hemiscorpius lepturus*. *Toxicon*. 50(7): 984–992.
 81. Yazdkhasti M, Razi Jalali M, Khadjeh GH, Jafari H, Rezaie A (2021) Cardiotoxic effects of *Hemiscorpius lepturus* scorpion venom fractions in rats. *Iran J Toxicol*. 15(1): 27–36.
 82. Viswanathan S, Prabhu C (2011) Scorpion sting nephropathy. *NDT Plus*. 4(6): 376–382.
 83. Boju SL, Mogili HKR, Ram R, Vishnubotla SK (2016) Nephrotic syndrome after scorpion sting. *CEN Case Rep*. 5(1): 83–86.
 84. Naqvi R, Naqvi A, Akhtar F, Rizvi A (1998) Acute renal failure developing after a scorpion sting. *Br J Urol*. 82(2): 295.
 85. de Sousa Alves R, do Nascimento NRF, Barbosa PSF, Kerntopf MR, Lessa LMA, De Sousa CM, Martins RD, Sousa DF, De Queiroz MGR, Toyama MH (2005) Renal effects and vascular reactivity induced by *Tityus serrulatus* venom. *Toxicon*. 46(3): 271–276.
 86. Albuquerque PLMM, Magalhaes KdN, Sales TdC, Paiva JHHGL, Daher EdF, Silva Junior GBd (2018) Acute kidney injury and pancreatitis due to scorpion sting: case report and literature review. *Rev Inst Med Trop Sao Paulo*. 60: e30.
 87. Saidani C, Hammoudi-Triki D, Larabadijebari F, Taub M (2016) In vitro studies with renal proximal tubule cells show direct cytotoxicity of *Androctonus australis hector* scorpion venom triggered by oxidative stress, caspase activation and apoptosis. *Toxicon*. 120: 29–37.
 88. Krkic-Dautovic S, Begovic B (2007) Acute renal insufficiency and toxic hepatitis following scorpions sting. *Med Arh*. 61(2): 123–124.
 89. Ranaweera G, Lokuhetty M, Bavanthan V, Nazar A (2015) Acute renal insufficiency after scorpion sting. *Ceylon Med J*. 60(1): 31–32.
 90. Dehghani R, Khamechian T, Vazirianzadeh B, Vatandoost H, Moravvej S (2012) Toxic effects of scorpion, *Hemiscorpius lepturus* (Hemiscorpiidae) venom on mice. *J Anim Plant Sci*. 22(3): 593–596.
 91. Movahed A, Fatemikia H, Tanha K, Esmaili A, Kim E, Dounighi NM, Zendeboodi S, Seyedian R (2018) Serological, pathological, and scintigraphic assessment of *Hemiscorpius lepturus* effects on renal dysfunction in rats. *Iran J Basic Med Sci*. 21(12): 1221–1225.
 92. Dehghani R, Dadpour B, Kassiri H, Vahabzadeh M, Sadat Izadi-Avanji F, Mohammadzadeh N (2019) Effects of the crude venom of *Hemiscorpius lepturus* (Scorpionida: Hemiscorpiidae) on mortality rate of white mice. *Biochem Cell Arch*. 19(1): 337–341.
 93. Pourkhalili K, Kim E, Mashayekhy NR, Kamyab M, Hoseiny SM, Evazy R,

- Mirakabadi AZ, Seyedian R (2015) Cardiotoxic and arrhythmogenic effects of *Hemiscorpius lepturus* scorpion venom in rats. *J Arthropod Borne Dis*. 9(2): 215–225.
94. Zabihollahi R, Bagheri KP, Keshavarz Z, Motevalli F, Bahramali G, Siadat SD, Momen SB, Shahbazzadeh D, Aghasadeghi MR (2016) Venom components of Iranian scorpion *Hemiscorpius lepturus* inhibit the growth and replication of human immunodeficiency virus 1 (HIV-1). *Iran Biomed J*. 20(5): 259–265.
95. Khaleghi Rostamkolaie L, Hamidinejat H, Razi Jalali M, Jafari H, Najafzadeh Varzi H, Seifi Abadshapouri M (2019) In vitro therapeutic effect of *Hemiscorpius lepturus* venom on tachyzoites of *Toxoplasma gondii*. *J Parasit Dis*. 43(3): 472–478.
96. Al-Malki ES, Abdelsater N (2020) In vitro Scolicidal effects of *Androctonus crassicauda* (Olivier, 1807) venom against the protoscolices of *Echinococcus granulosus*. *Saudi J Biol Sci*. 27(7): 1760–1765.
97. Lau JL, Dunn MK (2018) Therapeutic peptides: Historical perspectives, current development trends, and future directions. *Bioorg Med Chem*. 26(10): 2700–2707.
98. Maatuf Y, Geron M, Priel A (2019) The role of toxins in the pursuit for novel analgesics. *Toxins (Basel)*. 11(2): 131.
99. Moghadasi Z, Shahbazzadeh D, Jamili S, Mosaffa N, Bagheri KP (2020) Significant anticancer activity of a venom fraction derived from the Persian Gulf sea anemone, *Stichodactyla haddoni*. *Iran J Pharm Res*. 19(3): 402–420.
100. Zarghami V, Ghorbani M, Bagheri KP, Shokrgozar MA (2021) Melittin antimicrobial peptide thin layer on bone implant chitosan-antibiotic coatings and their bactericidal properties. *Mater Chem Phys*. 263: 124432.
101. Harvey A (2014) Toxins and drug discovery. *Toxicon*. 92: 193–200.
102. Carlsson KH, Jurna I (1987) Depression by flupirtine, a novel analgesic agent, of motor and sensory responses of the nociceptive system in the rat spinal cord. *Eur J Pharmacol*. 143(1): 89–99.