

Case Report

A Case of Extensive Wound Myiasis Caused by *Lucilia sericata* (Diptera: Calliphoridae) in a Patient with Maxillary Sinus Squamous Cell Carcinoma, in Turkey

*Filiz Demirel-Kaya¹, Ömer Orkun², Ayşe Çakmak², A. Çakan Kaya³, Murat Öcal¹, Sibel Ergüven¹

¹Department of Medical Microbiology, Hacettepe University Faculty of Medicine, Ankara, Turkey

²Department of Parasitology, Ankara University Faculty of Veterinary Medicine, Ankara, Turkey

³Department of Internal Medicine, Infectious Diseases Unit, Hacettepe University Faculty of Medicine, Ankara, Turkey

(Received 8 Apr 2014; accepted 10 Aug 2014)

Abstract

The larvae causing myiasis can lead extensive tissue destruction, invasion into deep tissues and secondary infections. Poor hygiene, low socioeconomic condition and presence of open wounds are the most important predisposing factors. This case report describes destructive wound myiasis in a 58-year-old male patient diagnosed with maxillary sinus squamous cell carcinoma who lives in a rural area in Ankara, Turkey. Approximately 200 larvae were collected and identified as *Lucilia sericata* by morphological examination. Myiasis should be considered especially when the patient has open extensive lesions such as malignant wounds.

Keywords: Myiasis, Squamous cell carcinoma, *Lucilia sericata*

Introduction

Myiasis is defined as the parasitic infestation of tissues and organs in living vertebrates with dipterous larvae which at least for a certain period, feed on the host's living or dead tissue, mucosa, liquid body substance or digested food (Hope 1840, Zumpt 1963).

Myiasis is seen more typically in tropical and subtropical countries. Low socioeconomic status, poor sanitation, advanced age and vascular disorders are the most important risk factors for myiasis (Francesconi and Lupi 2012).

The clinical manifestation of myiasis depends on the genus and species of fly, the degree of invasion by larvae, the stage of the fly, number of larvae and the site of invasion. Skin involvement is the most seen clinical manifestation. Cutaneous myiasis includes furuncular, migratory and wound myiasis (Zumpt 1963, Francesconi and Lupi 2012).

A broad range of flies can cause myiasis in

humans, especially members of Oestridae, Calliphoridae and Sarcophagidae families are reported (Scholl 2002). *Lucilia sericata* flies belonging to the Calliphoridae family are very common flies in the temperate zone of Northern hemisphere. They can cause myiasis in humans and domestic animals (Lane and Crosskey 1993).

Diagnosis of myiasis depends on the demonstration of larvae on the patient's tissues or organs. It is important to make the correct identification of the larvae for planning the treatment and promoting preventing measures (Francesconi and Lupi 2012).

Case presentation

In this report, a case of maxillary sinus carcinoma complicated with myiasis was presented. A 58-year-old male patient living

in a rural area with low socioeconomic condition, admitted to the Hacettepe University Department of Emergency Medicine, Ankara, Turkey in July 2013, because of a suppurated, massive destructive lesion containing numerous larvae covering left half of his face. The patient had poor general condition. He was diagnosed maxillary squamous cell carcinoma five years ago, and catatonic schizophrenia. He had been operated four times because of his tumour before.

The tumoural lesion of the patient was covered the left maxillary-orbital region and nose and there were a great number of larvae moving in his tumour lesion (Fig. 1). Approximately 200 larvae were removed from his wound by mechanical and the lesion was rinsed using hydrogen peroxide solution. Some of the larvae delivered to the parasitology laboratory. After morphological examination the larvae washed in distilled water and killed in alcohol 70 % and they were taken to the Ankara University Veterinary Faculty Department of Parasitology for identification. The morphological characters of cephalo-pharyngeal skeleton, anterior spiracles and slits of the posterior spiracles were examined. Measured length of 10–15 larvae were about 12 to 16 mm (Fig. 2). The anterior spiracles with 7–9 lobes, the posterior spiracles with narrow and complete peritreme, straight and parallel 3 slits and cephalo-pharyngeal skeleton without accessory oral sclerite were observed by microscopically (Fig. 3). We also observed inner, median, outer and anal tubercles on the posterior segment of the larvae and the distance between the tubercles on the top side of the posterior cavity was equal. The larvae were identified as 3rd instar of *L. sericata*. Because of all the larvae were dead we could not rear the larvae to adult stage.

The patient's white blood cell count and C-reactive protein values were found high so meropeneme therapy was started. He had severe protein-energy malnutrition because of

unabling to eat and a dietary supplement was intended. The patient was taken to the Department of Otorhinolaryngology for palliative operation for his tumour. Excision of mass, total left maxillectomy, total parotidectomy, partial mandibulectomy and rinectomy was performed.

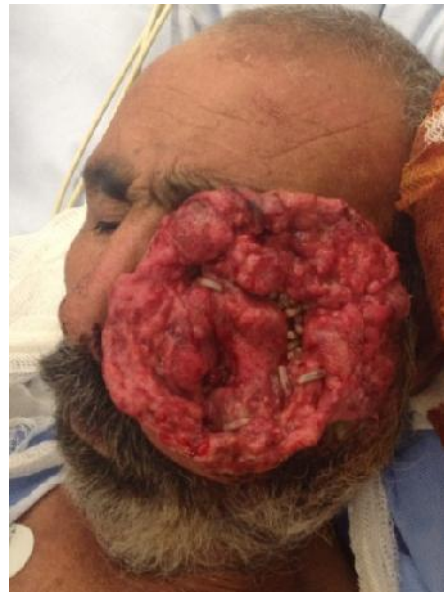

Fig. 1. Extensive destructive lesion of the maxillary-orbital region of the face with a lot of larvae inside

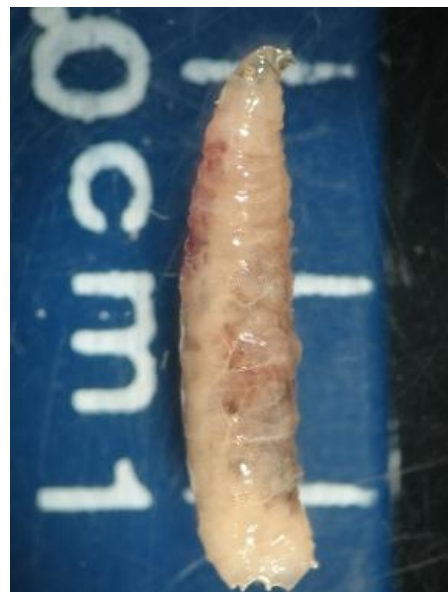

Fig. 2. Macroscopic aspect of a larva

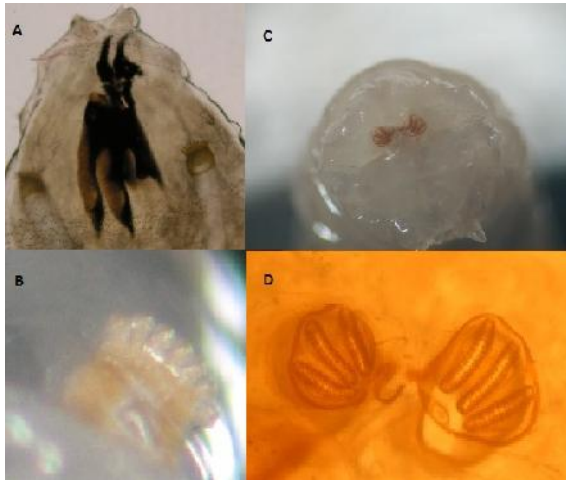


Fig. 3. A) Cephalopharyngeal skeleton, B) Anterior spiracle, C-D) Posterior spiracle

Conclusion

Lucilia sericata flies belong to Caliphoridae family which can cause myiasis in humans and domestic animals. The adult flies of the *L. sericata* species are metallic green and they are known as greenbottles. Females can deposit their eggs in neglected and suppurating wounds. The larvae hatch in a few days and feed on the tissues and exudates (Lane and Crosskey 1993).

In humans, first case of myiasis due to *L. sericata* was reported in 1826 by Magen from mouth, eyes and paranasal sinuses of a patient. In literature there are several reports of cases with myiasis by *L. sericata*. Talari et al. (2004) reported a wound myiasis in a heroin addicted patient. Kılıç et al. (2011) presented a postoperative wound myiasis caused by *L. sericata* in a woman who had breast cancer surgery. Myiasis is one of the most undesirable conditions in cancer patients with malignant cutaneous wounds and a rare complication of squamous cell carcinoma. Sesterhenn et al. (2009) reported a case of wound myiasis in an extensive skin metastasis of oral squamous cell carcinoma and they identified the larvae as *Lucilia* sp. Gabriel et al. (2008) presented a case of

myiasis in a patient with extensive head and neck squamous cell carcinoma. Pessoa et al. (2011) reported myiasis infestation in a patient with invasive oral squamous cell carcinoma with ulcerated necrotic wound. In all of these patients, open neglected wounds and poor hygiene are the most important predisposing factors leading the infestation with larvae. Living in a rural area, advanced age and low socioeconomic conditions are also risk factors (Demirel-Kaya et al. 2014).

Psychiatric disorder, low socio-economic level and poor hygiene are the most important predisposing factors that lead to the development of myiasis in this patient as well as the presence of an open, extensive neglected wound. It should be kept in mind that the cancer patients with open wounds may develop myiasis especially in the summer months and larvae can cause progressive wound infection.

Sometimes the presence of larvae is useful for the wounds. Maggot therapy is the medically use of sterile fly larvae in treatment of resistant wounds. Larvae can debride and clean wounds and promote healing. *L. sericata* is usually used for the maggot therapy (Falch et al. 2009). It has been also demonstrated that some of the enzymes and substances secreted by 2nd and 3rd instar of the *L. sericata* larvae have bacteriostatic and bactericidal effects and by this way the larvae can disinfect the lesions. (Polat et al. 2012).

Acknowledgements

The authors declare that there is no conflict of interest.

References

- Demirel Kaya F, Orkun O, Cakmak A, Inkaya AC, Erguven S (2014) Human cutaneous myiasis caused by larvae of

- Sarcophaga* spp. in a diabetic patient. Mikrobiyol Bul. 48(2): 356–361.
- Falch BM, de Weerd L, Sundsfjord A (2009) Maggot therapy in wound management. Tidsskr Nor Laegeforen. 129(18): 1864–1867.
- Francesconi F, Lupi O (2012) Myiasis. Clin Microbiol Rev. 25(1): 79–105.
- Gabriel JG, Marinho SA, Verli FD, Krause RG, Yurgel LS, Cherubini K (2008) Extensive myiasis infestation over a squamous cell carcinoma in the face. Med Oral Patol Oral Cir Bucal. 13(1): E9–11.
- Hope FW (1840) On insects and their larvae occasionally found in the human body. Trans R Soc Entomol. 2: 256–271.
- Kılıç K, Arslan MÖ, Kara M (2011) A post-operative Wound Myiasis Caused by *Lucilia sericata* (Diptera: Calliphoridae) in a Woman in Kars. Turkiye Parazitoloj Derg. 35: 43–46.
- Lane RP, Crosskey RW (1993) Diptera causing myiasis in man In: Lane RP and Crosskey RW (Eds): Medical Insects and Arachnids, Chapman and Hall, London, pp. 429–451.
- Pessoa L, Galvao V (2011) Myiasis infestation in advanced oral squamous cell carcinoma. BMJ Case Rep. doi:10.1136/bcr.04.2011.4124.
- Polat E, Cakan H, Aslan M, Sirekbasan S, Kutlubay Z, Ipek T, Ozbilgin A (2012) Detection of anti-leishmanial effect of the *Lucilia sericata* larval secretions in vitro and in vivo on *Leishmania tropica*: first work. Exp Parasitol. 132(2): 129–134.
- Scholl PJ, Catts EP, Mullen GR (2002) Myiasis. In: Mullen GR and Durden LA (Eds): Med Vet Entomol. 2nd ed. Elsevier, USA, pp. 309–338.
- Sesterhenn AM, Pftzner W, Bräulke DM, Wiegand S, Werner JA, Taubert A (2009) Cutaneous manifestation of myiasis in malignant wounds of the head and neck. Eur J Dermatol. 19(1): 64–68.
- Talari SA, Sadr F, Doroodgar A, Talari MR, Gharabagh AS (2004) Wound myiasis caused by *Lucilia Sericata*. Arch Iranian Med. 7(2): 128–129.
- Zumpt F (1963) The problem of intestinal myiasis in humans. S Afr Med J. 37: 305–307.